

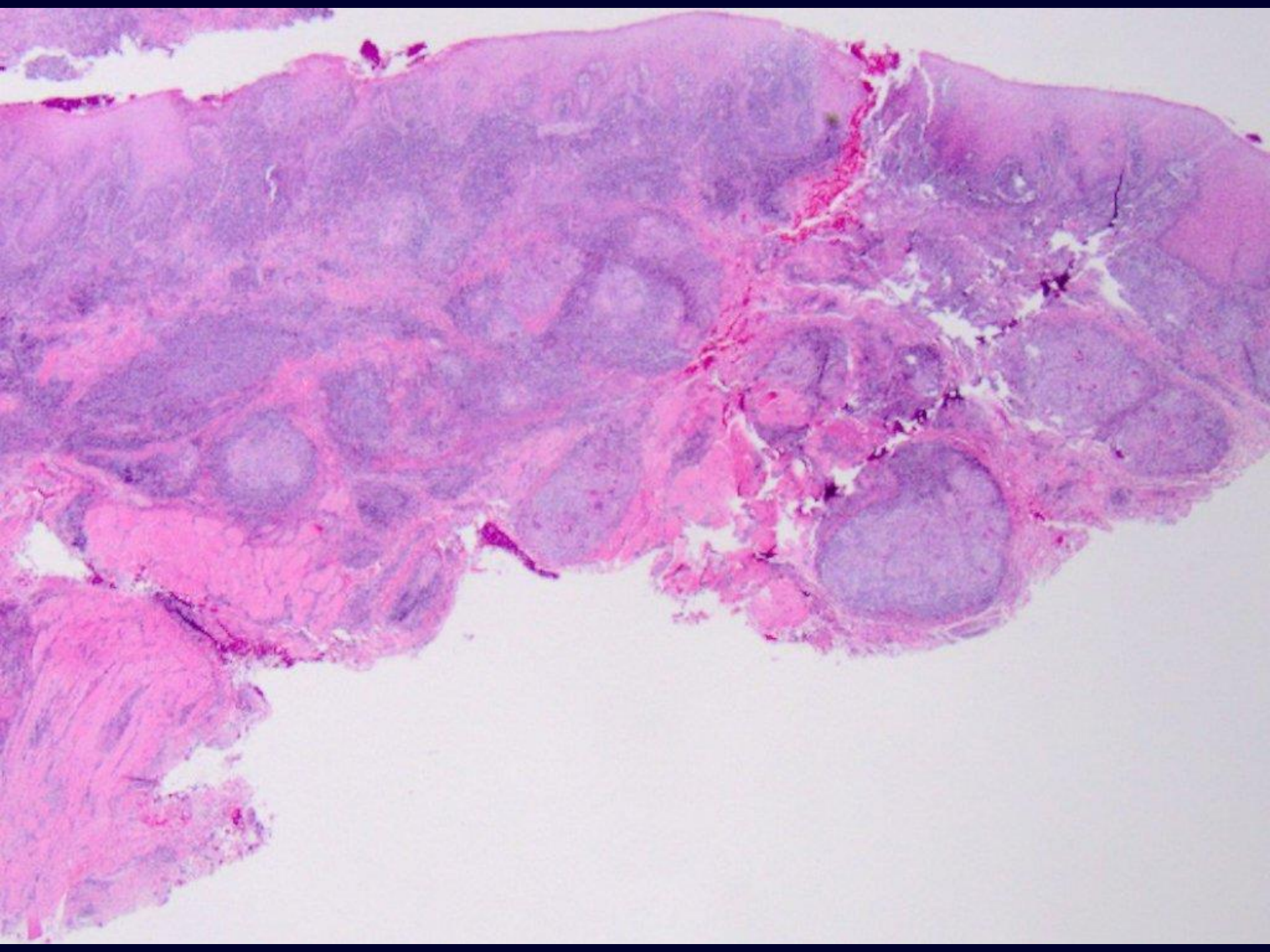
Oral Histopathology

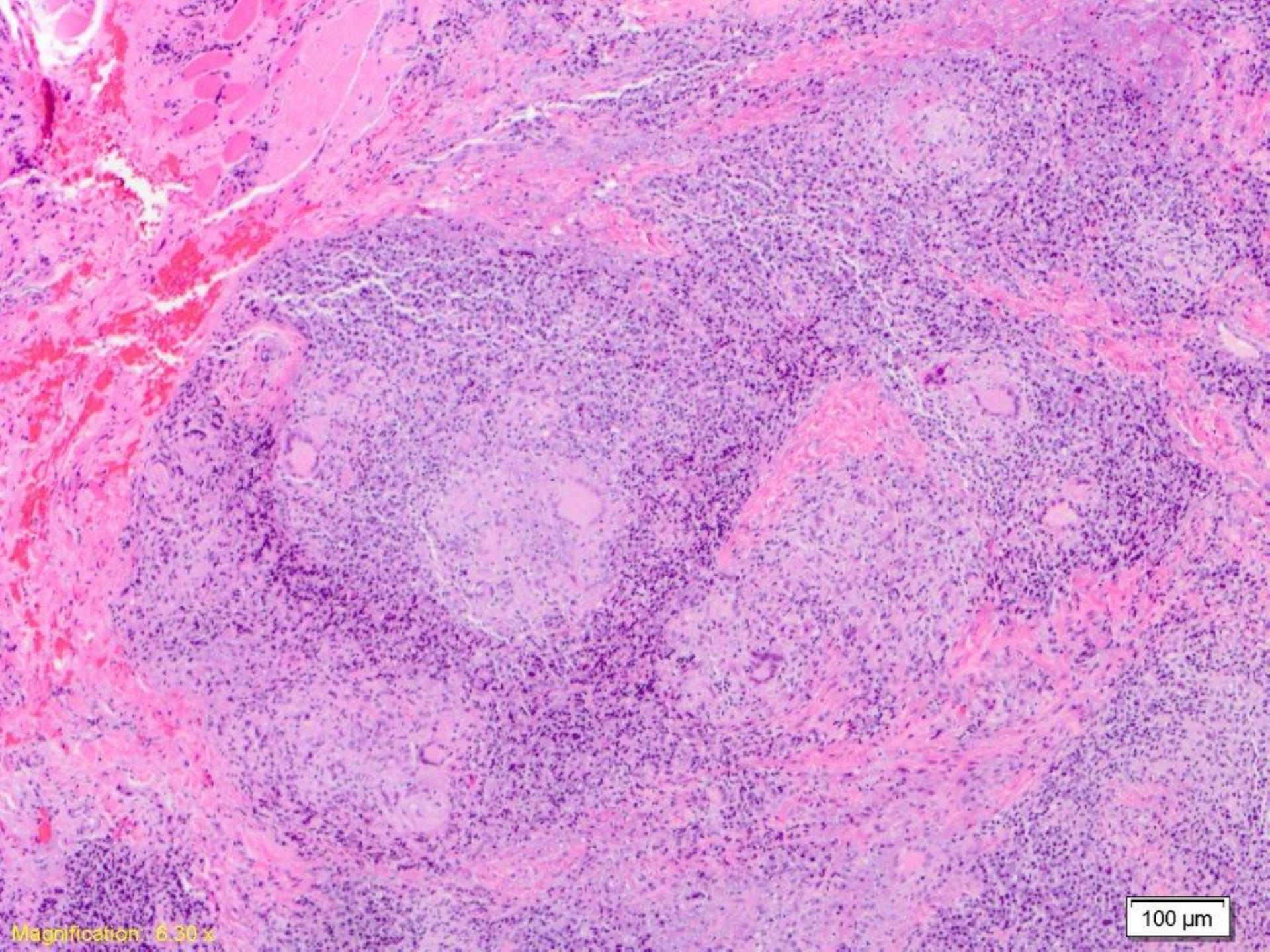
Series 36

DAVID E. KLINGMAN, DMD

Diplomate, American Board of Oral and Maxillofacial Pathology

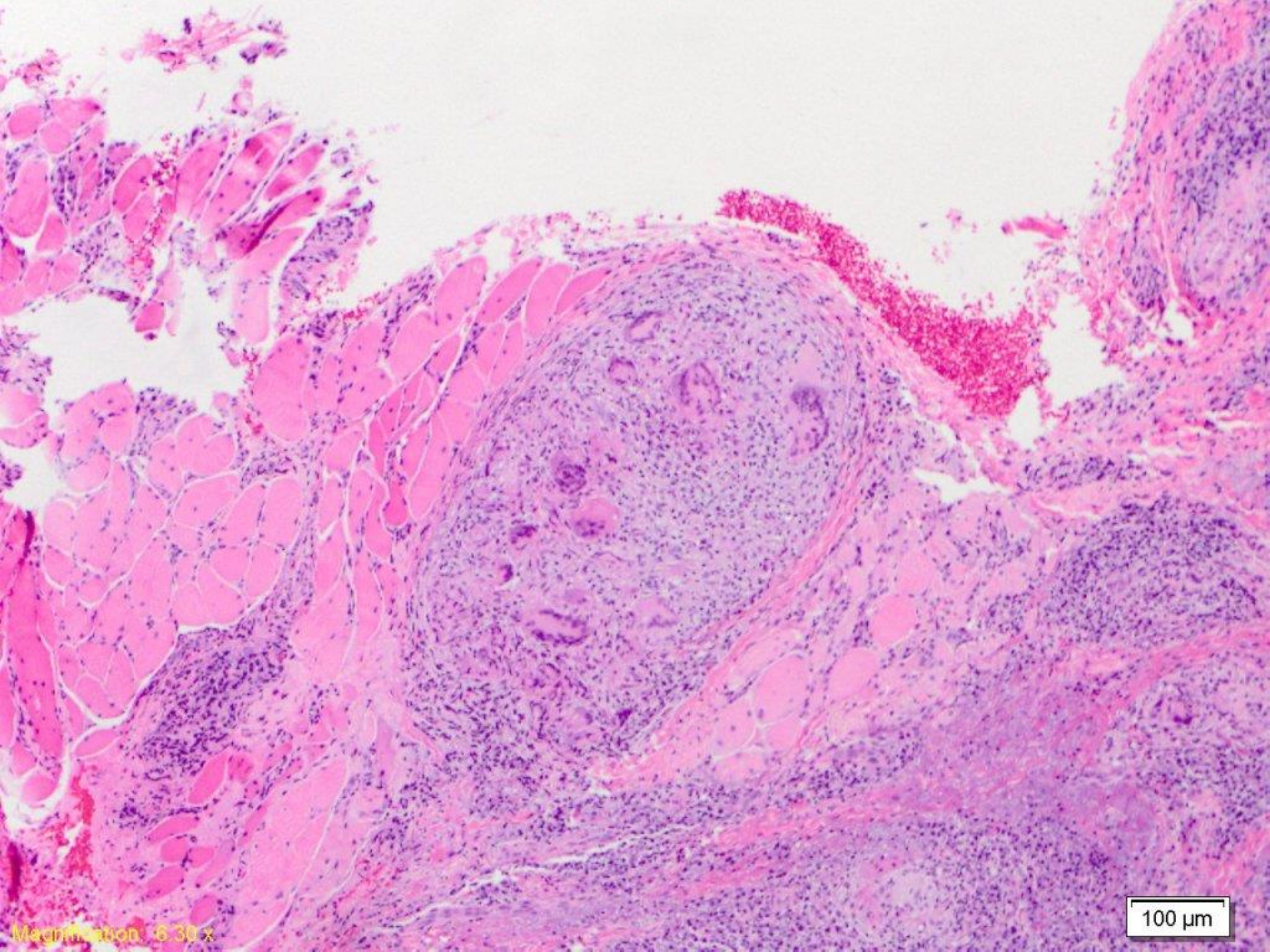
Diplomate, American Board of General Dentistry





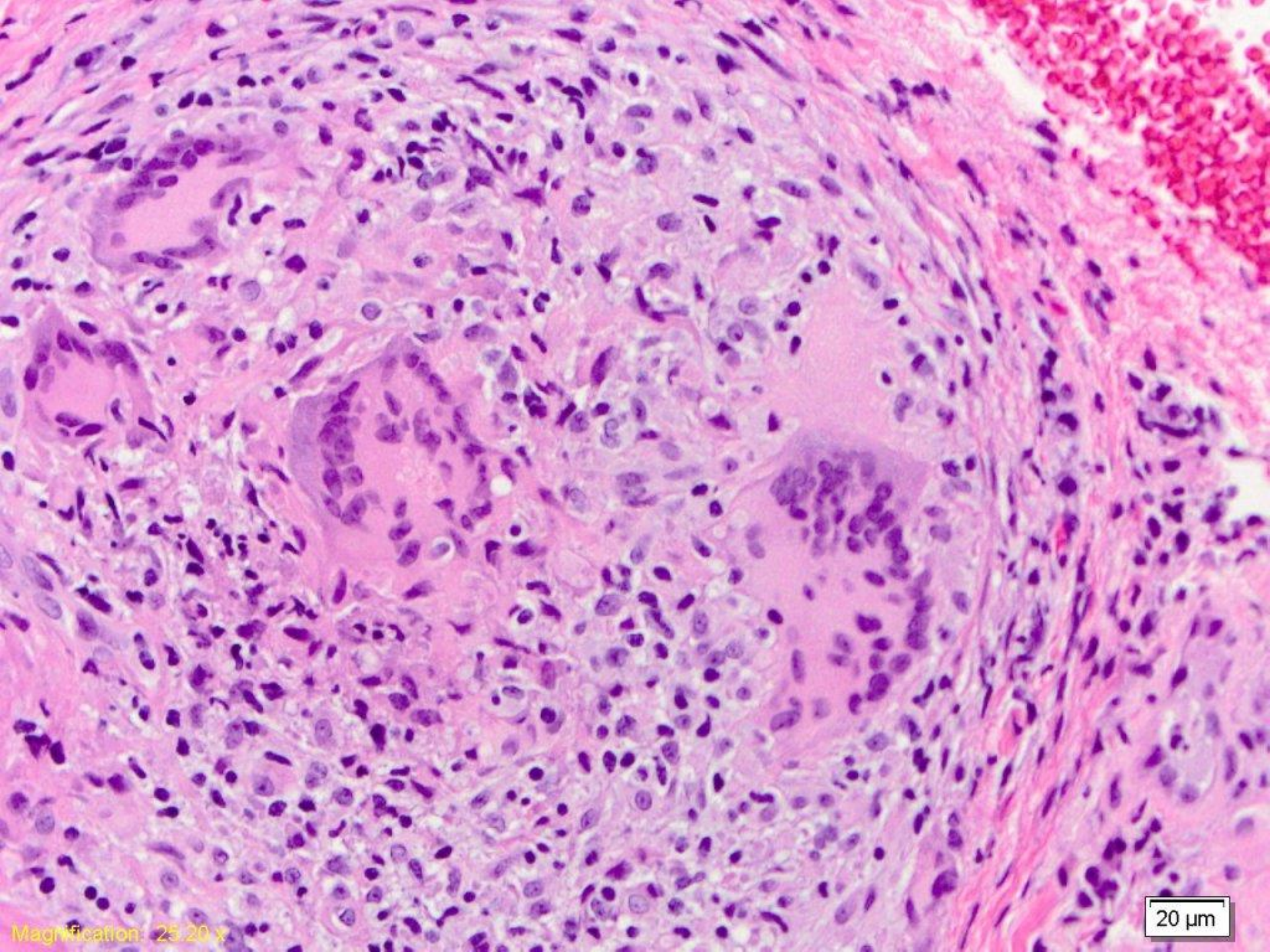
Magnification: 6.30 x

100 μ m



Magnification: 630x

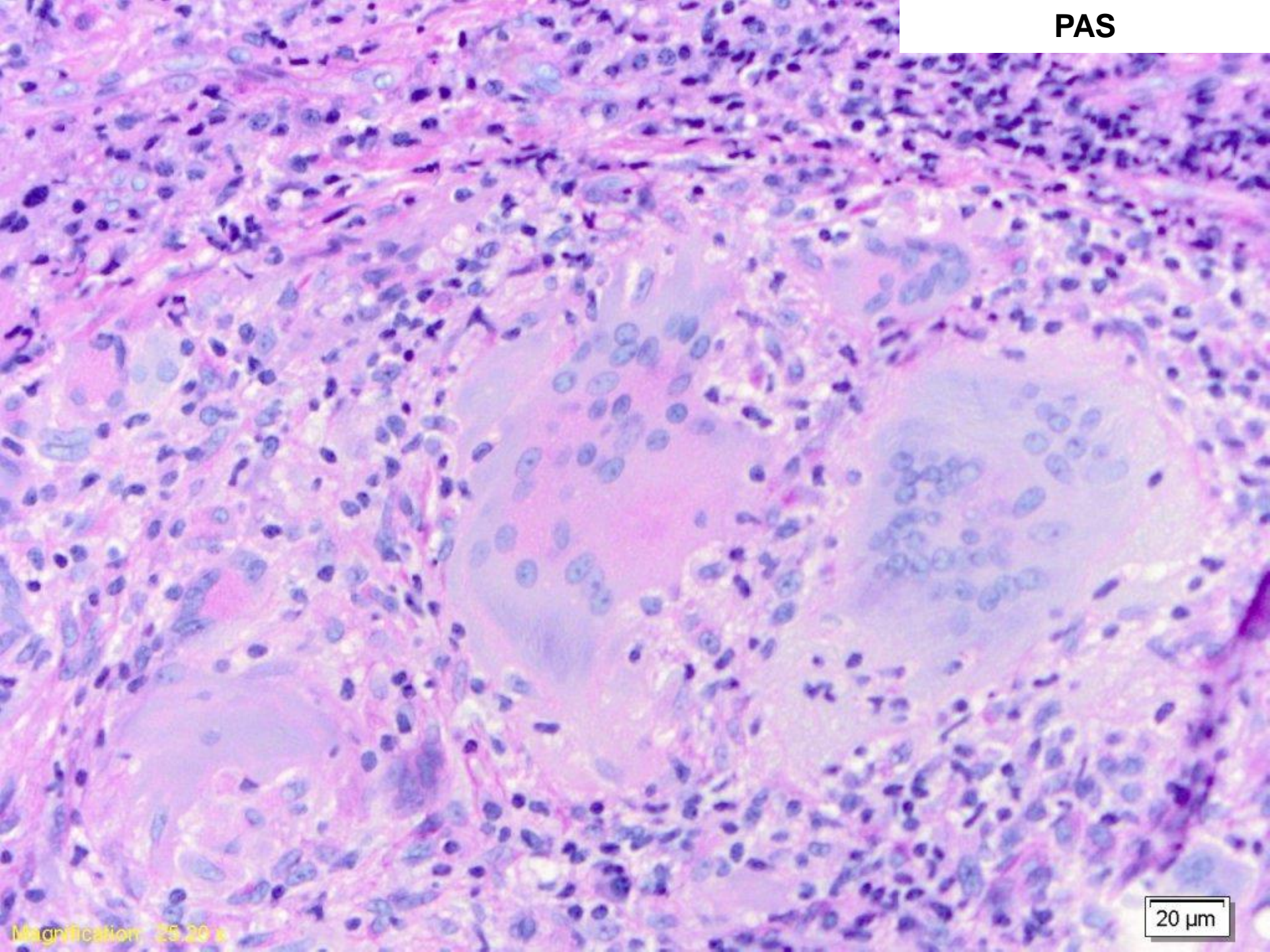
100 μ m



Magnification: 25.20 x

20 μ m

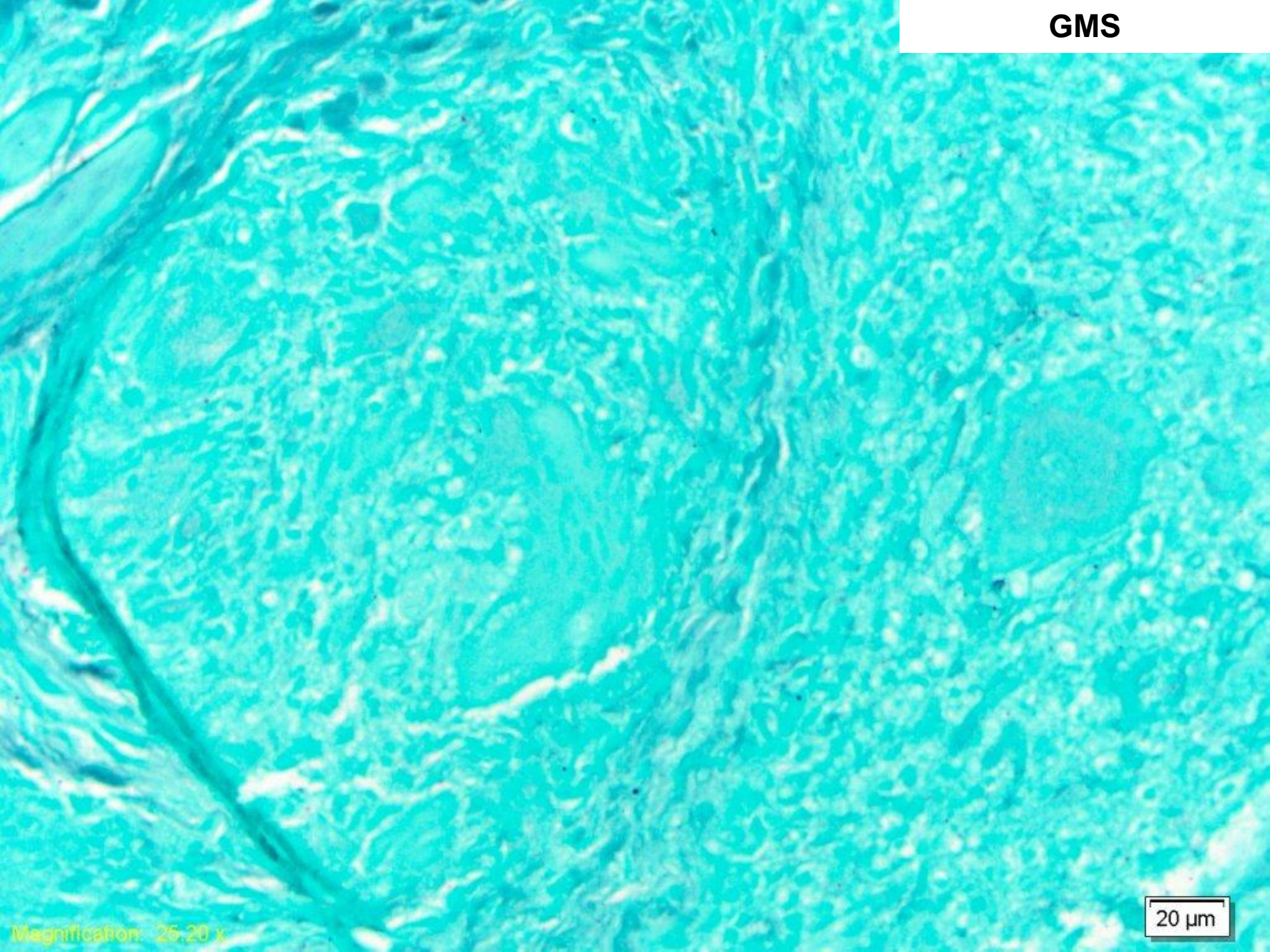
PAS



Magnification: 25.29 x

20 μ m

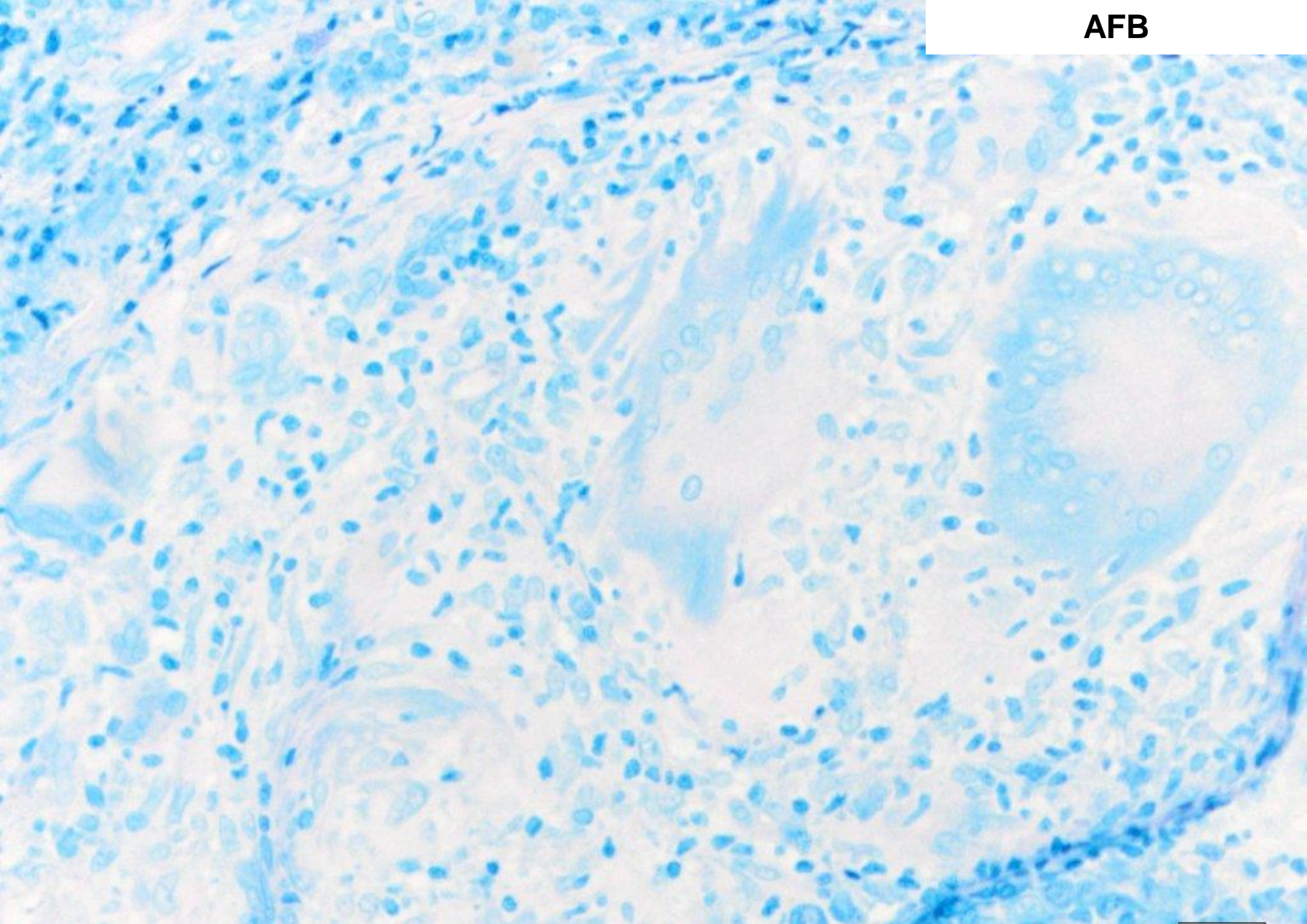
GMS



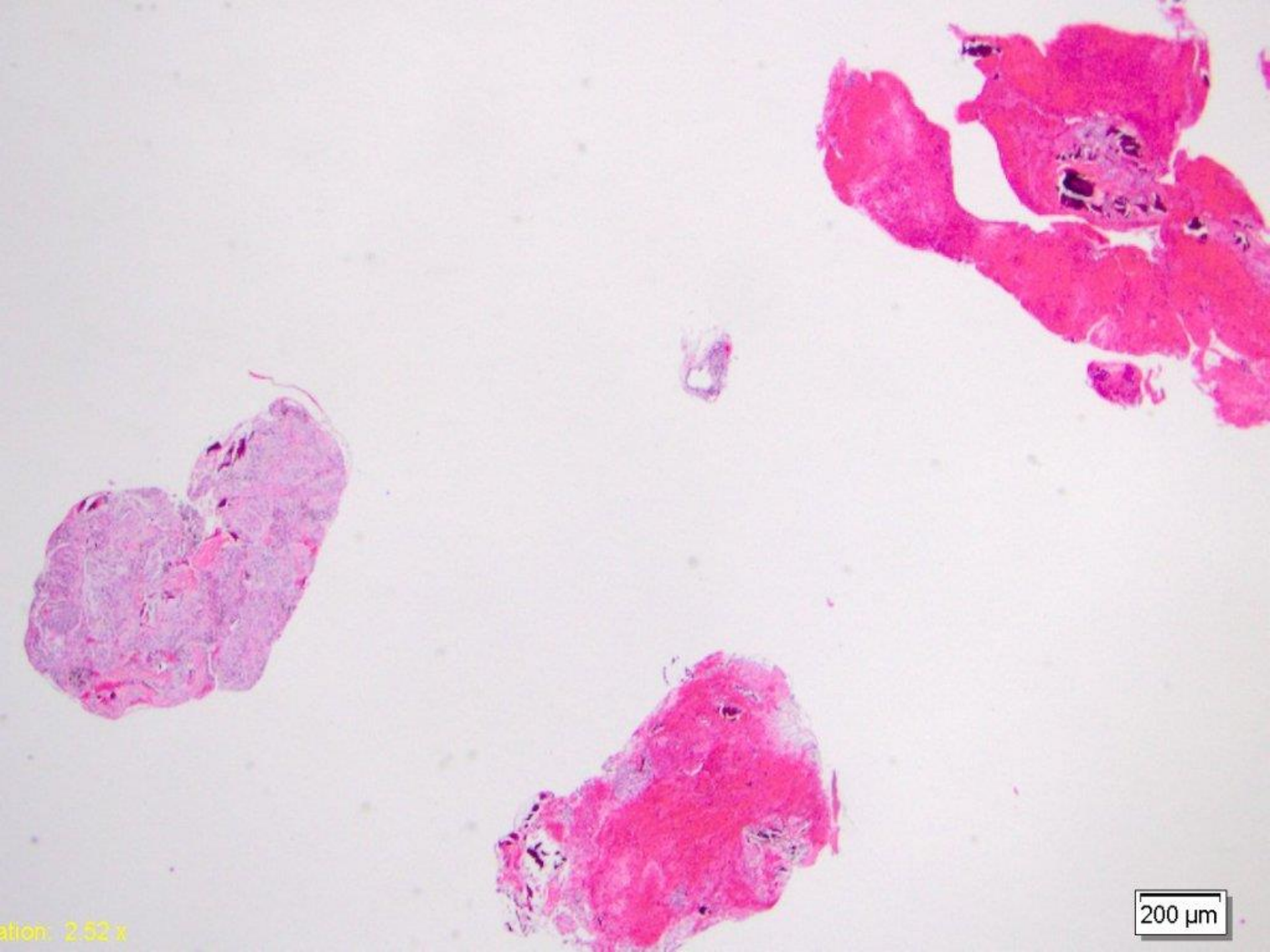
Magnification: 25.20 x

20 μ m

AFB

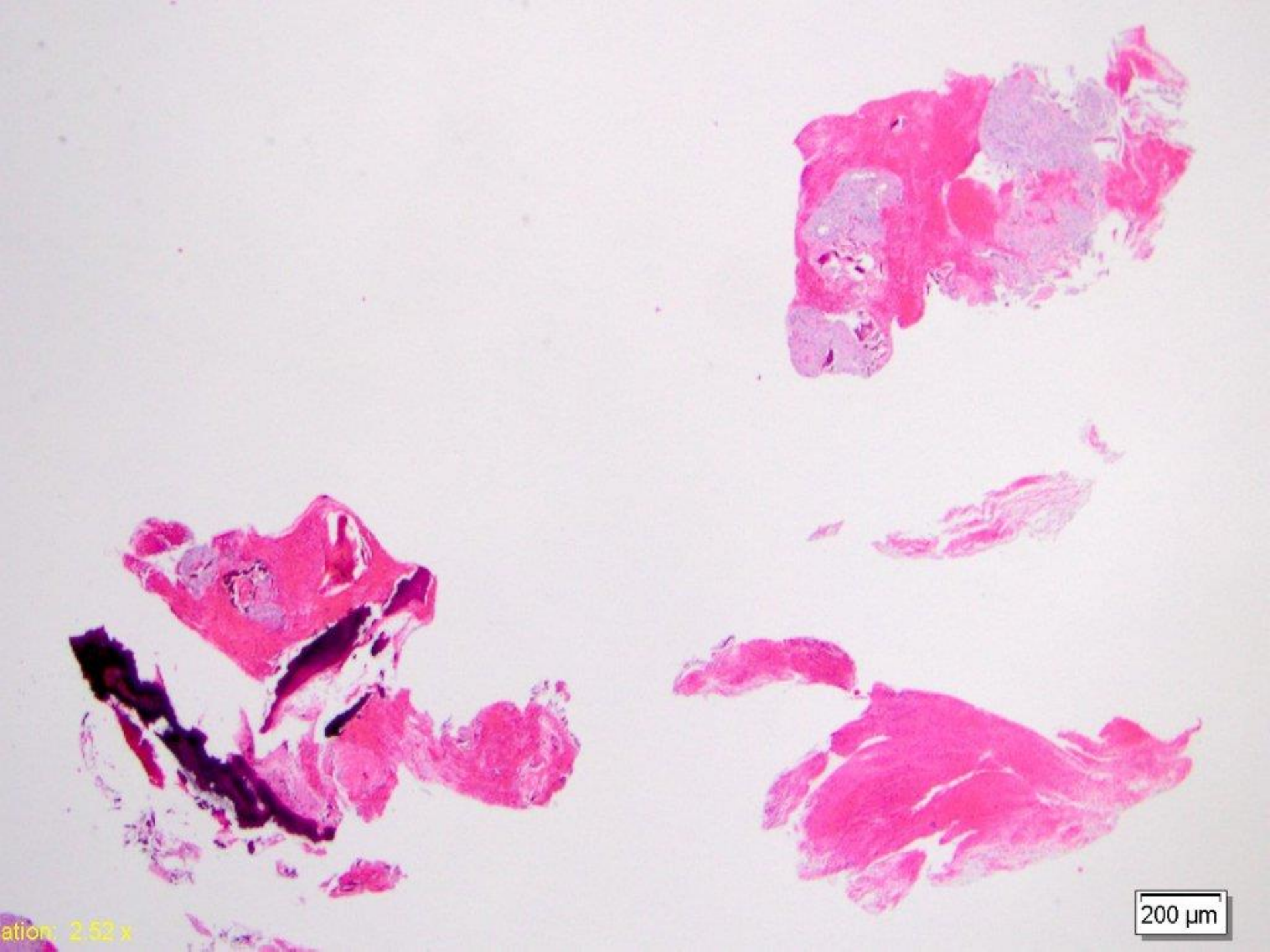


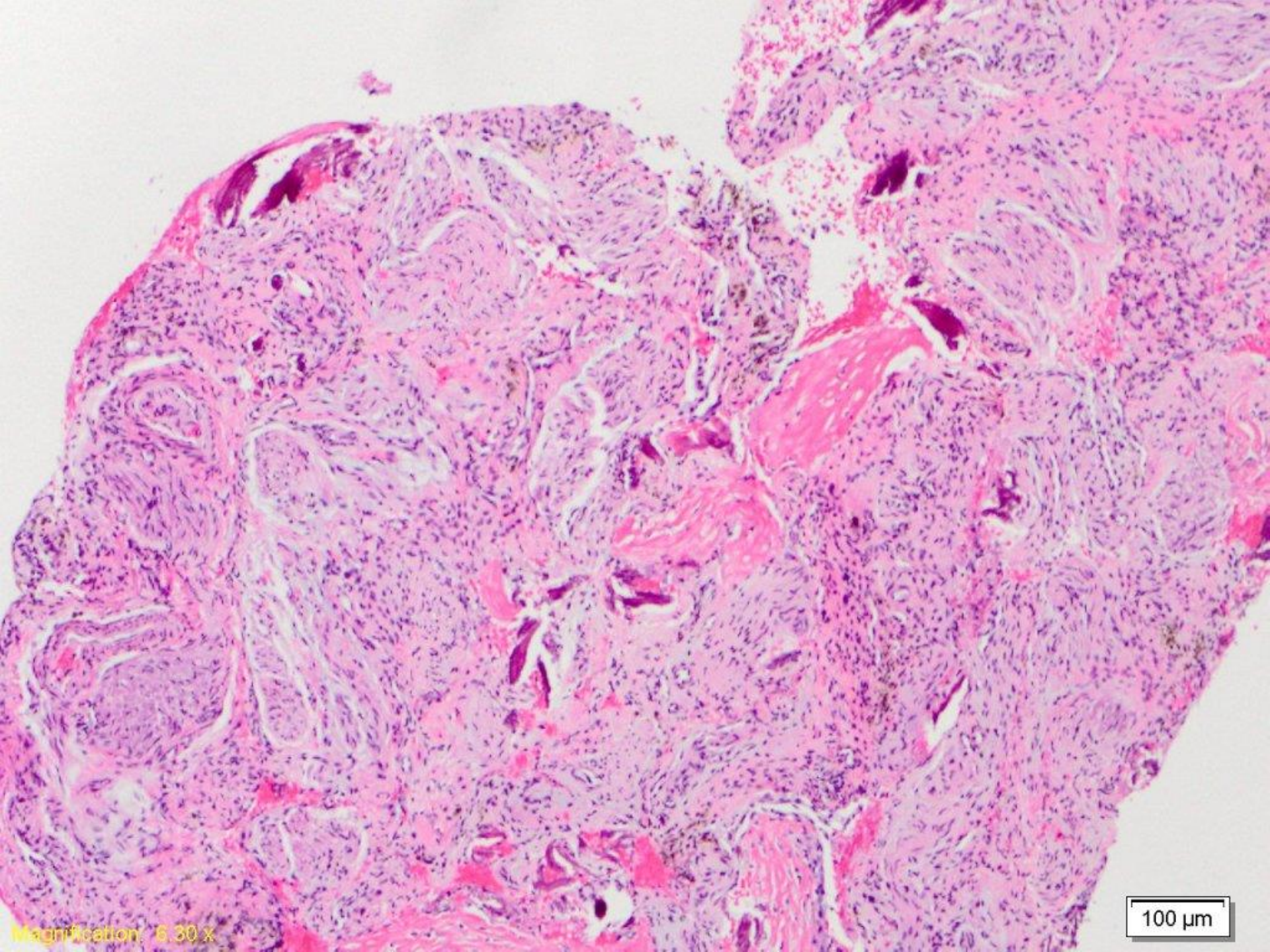
granulomatous inflammation, known history of Crohn's disease



ation: 2.52 x

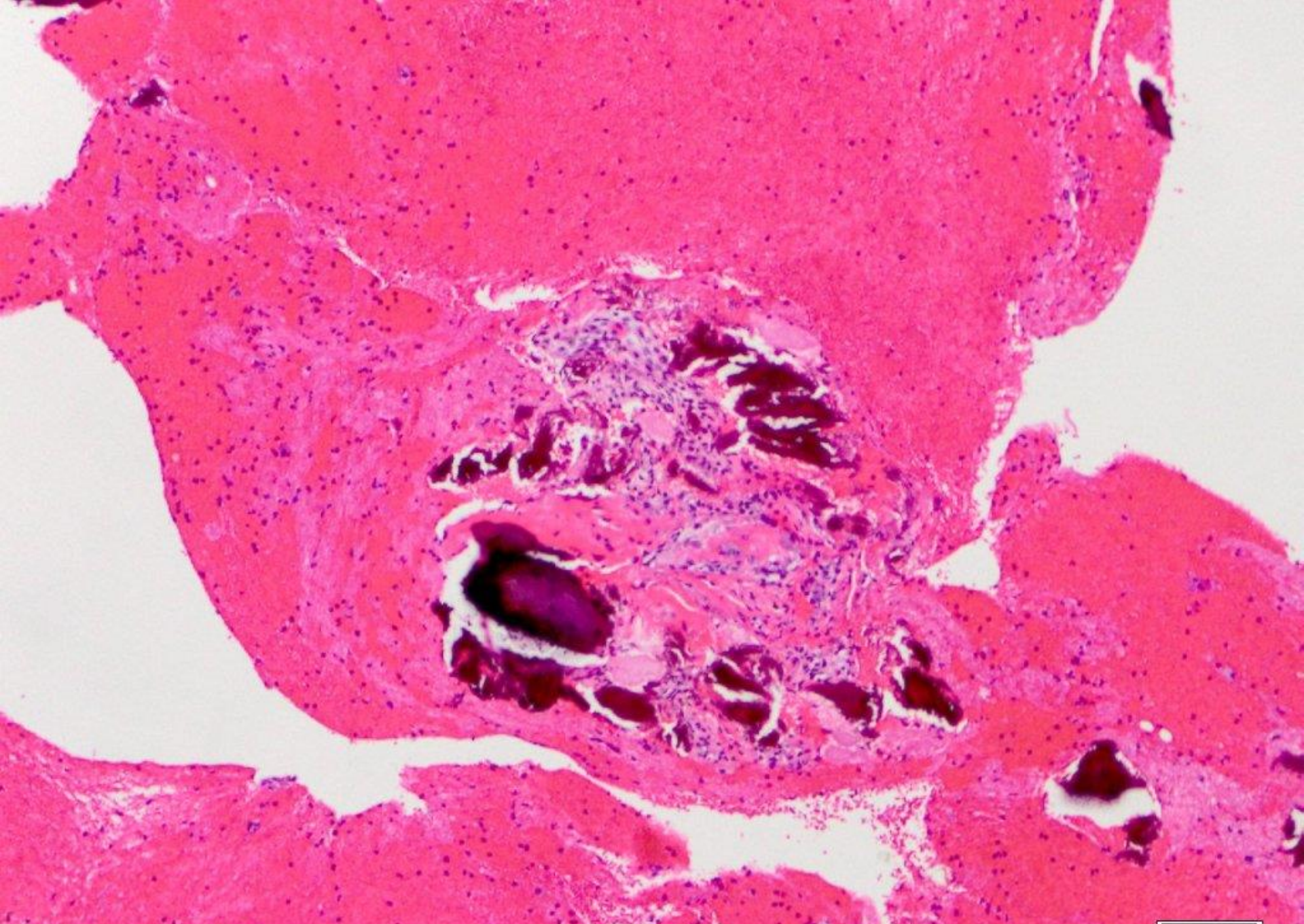
200 μm





Magnification: 630 x

100 μ m

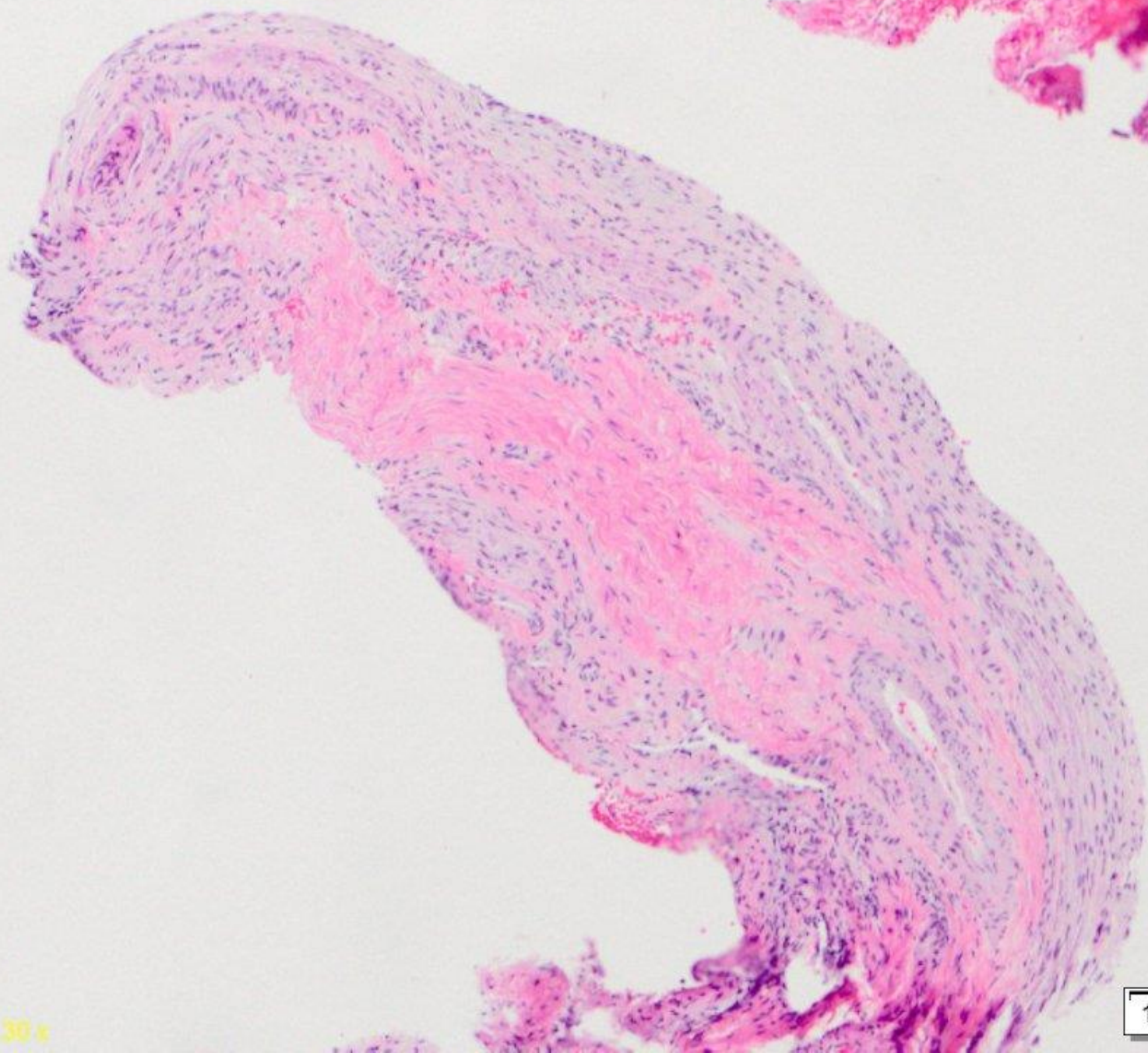


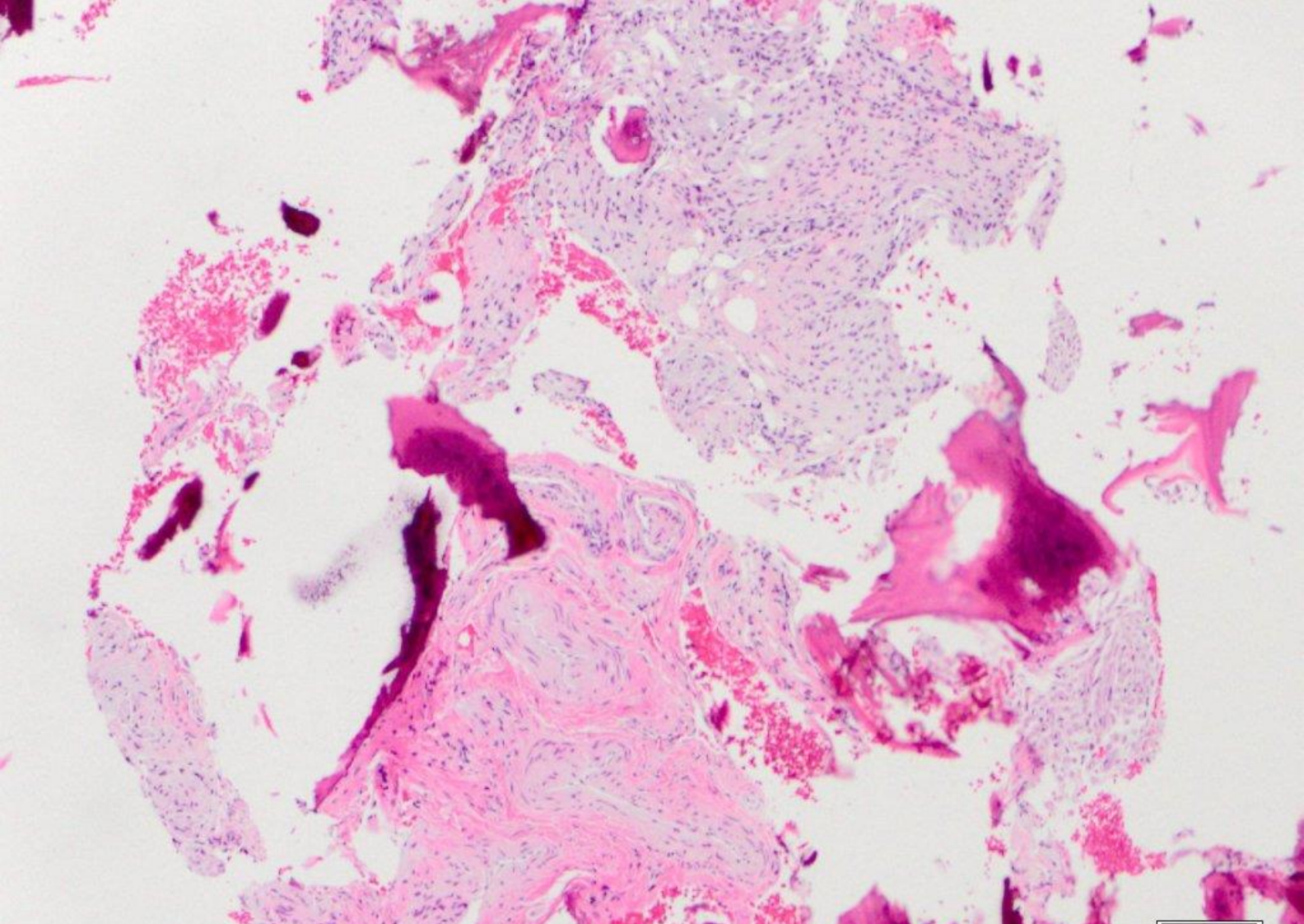
simple (hemorrhagic, traumatic, solitary) bone cyst



Magnification: 6.30 x

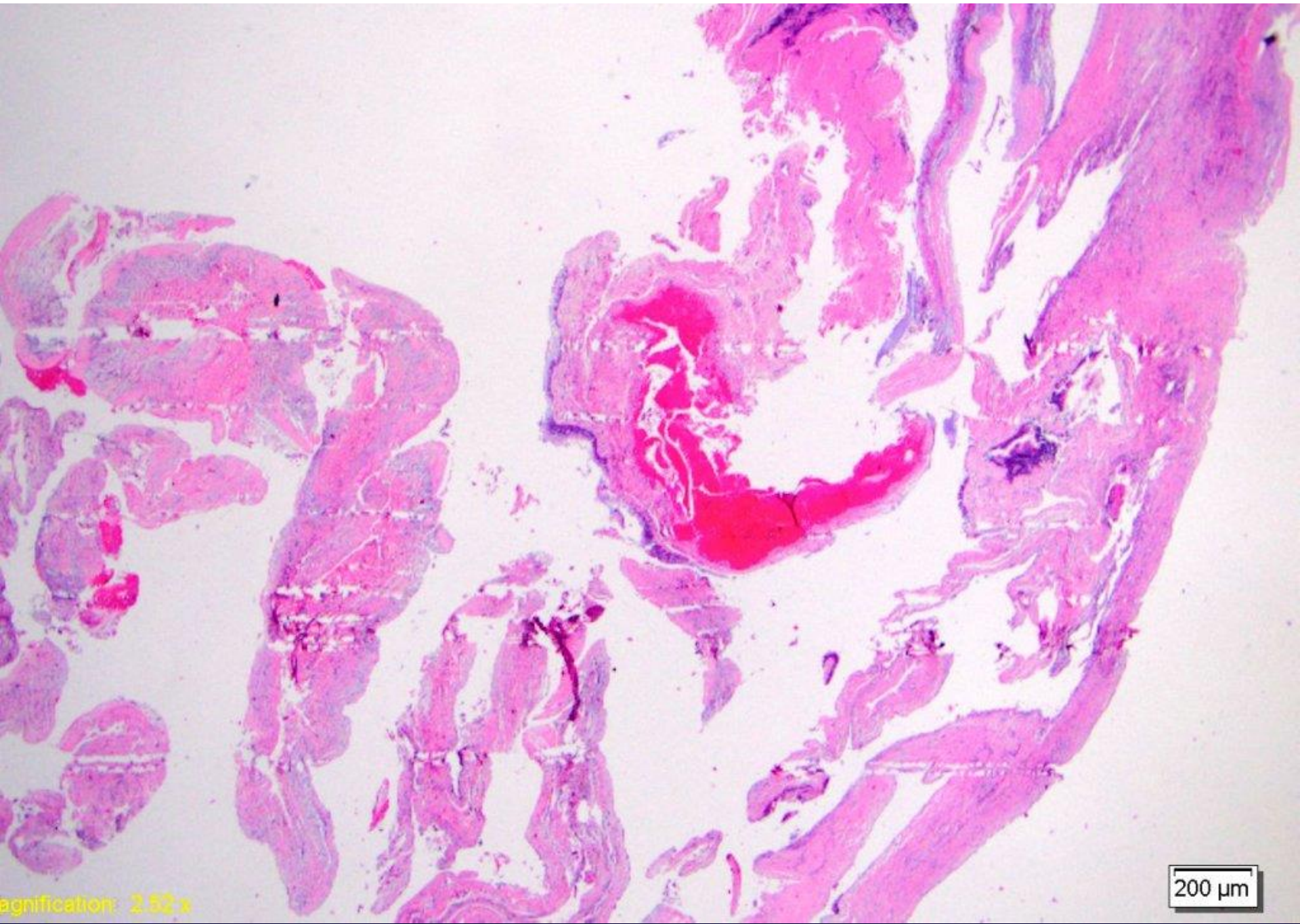
100 μ m





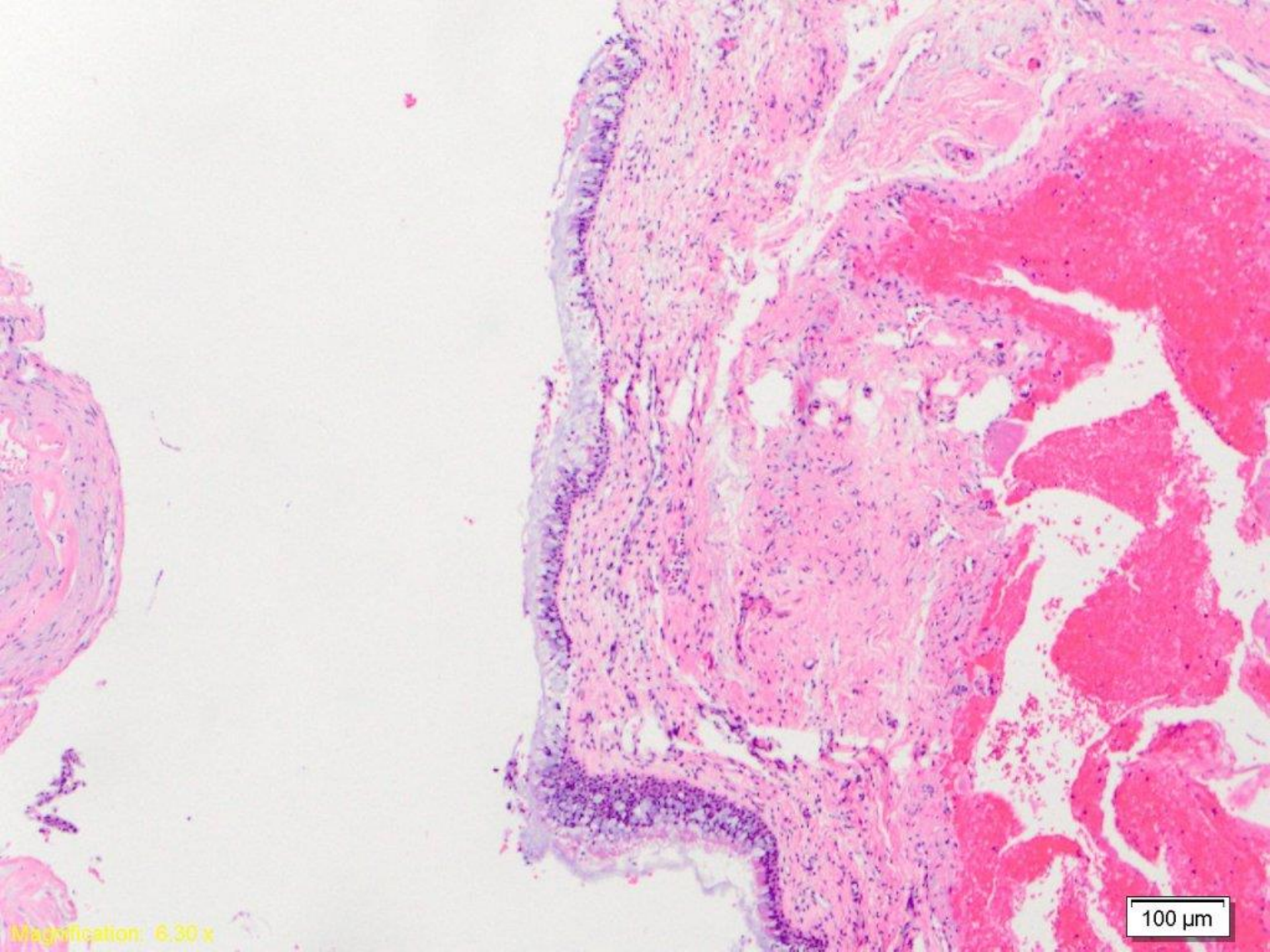
simple (hemorrhagic, traumatic, solitary) bone cyst

history of implant placement and sinus lift, maxilla



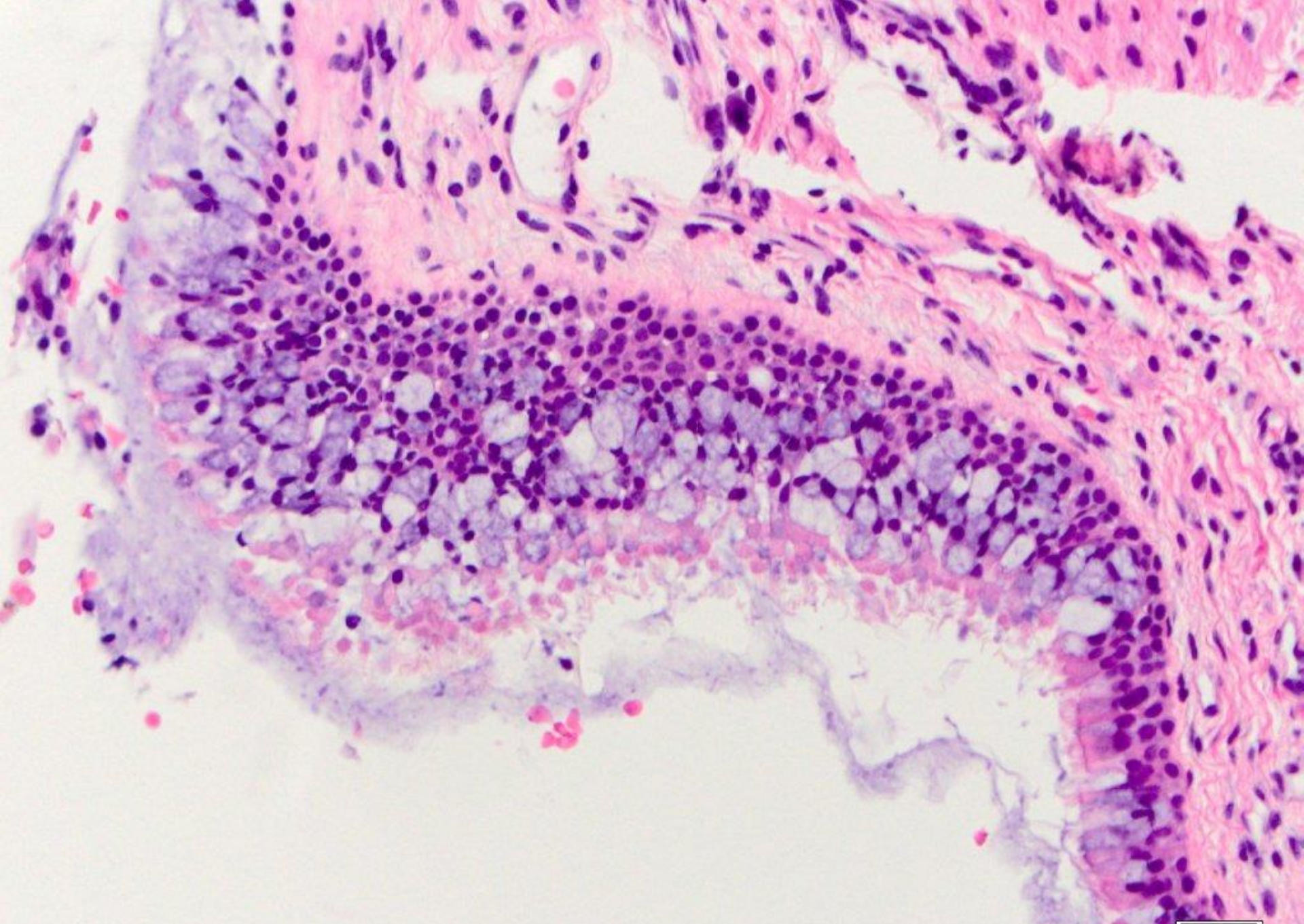
magnification: 2.52x

200 μ m

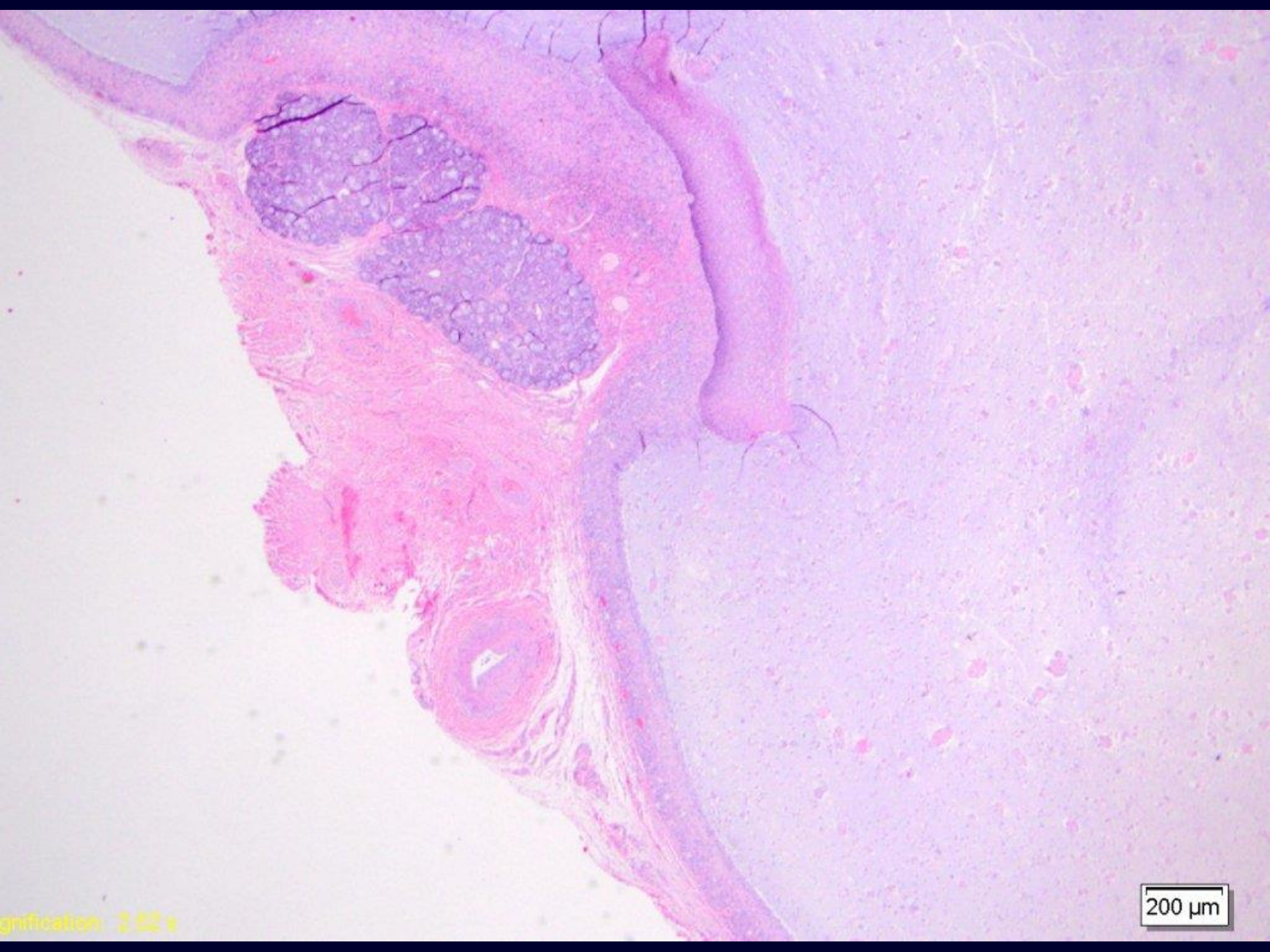


Magnification: 6.30 x

100 μ m

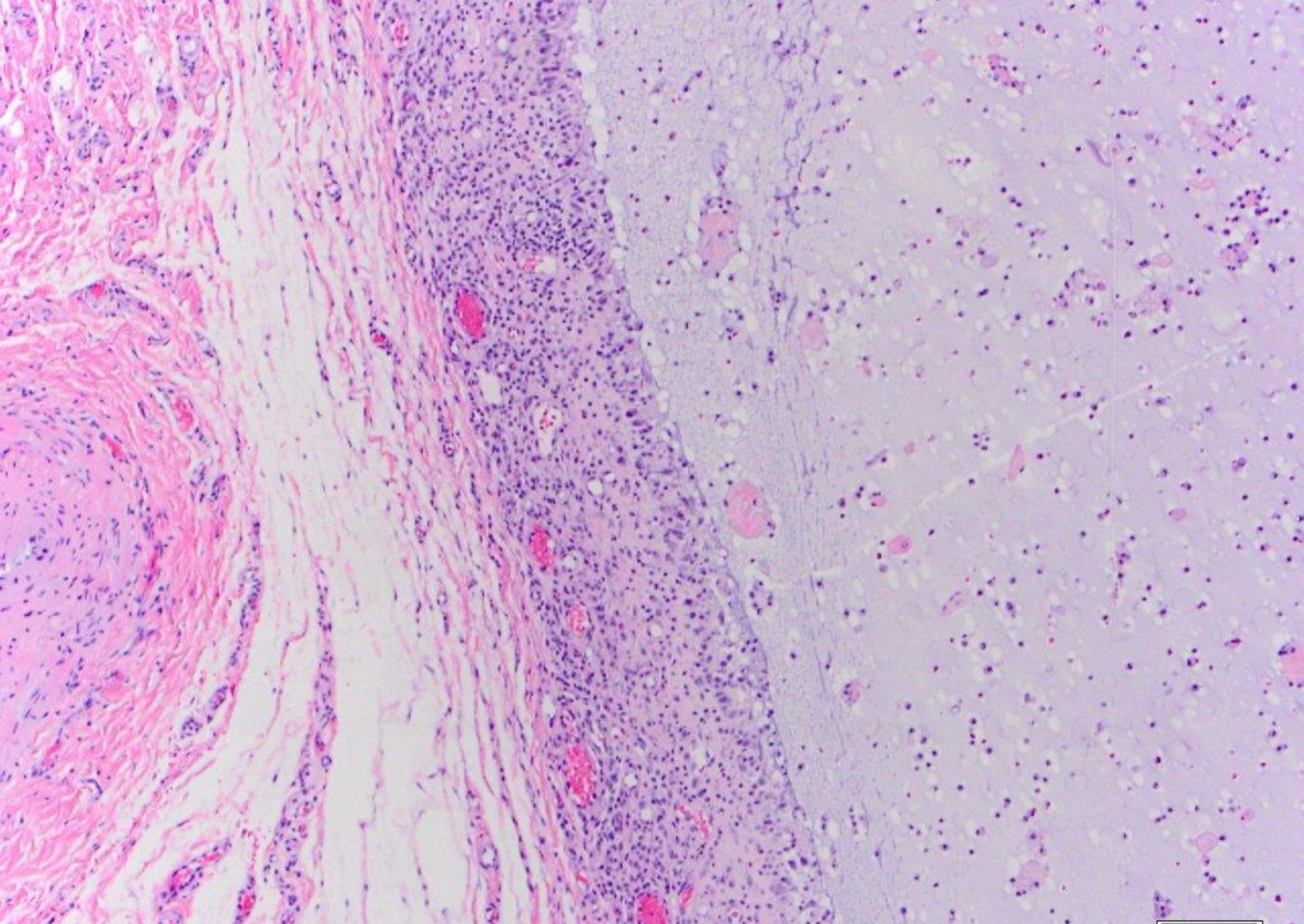


surgical ciliated cyst

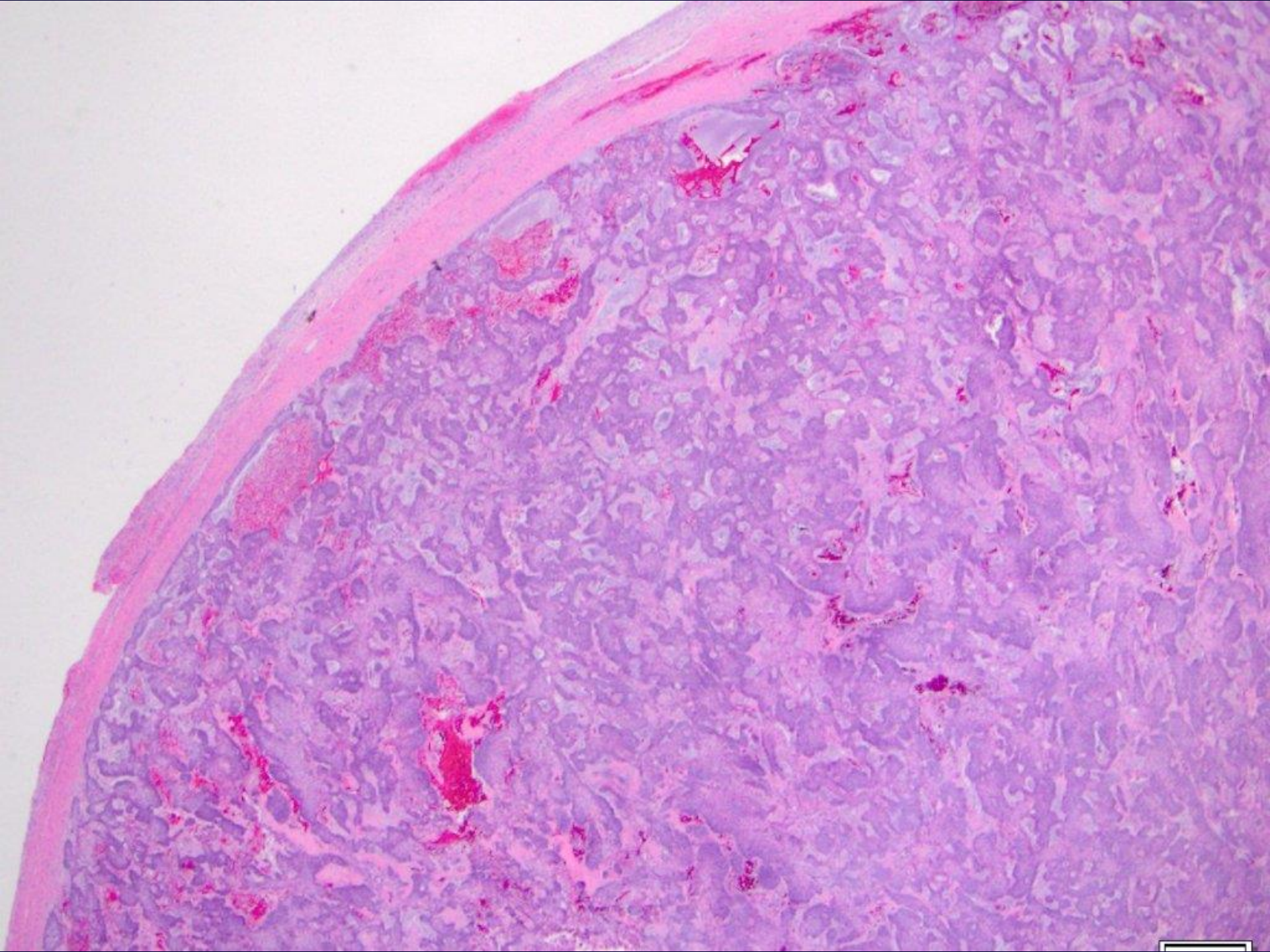


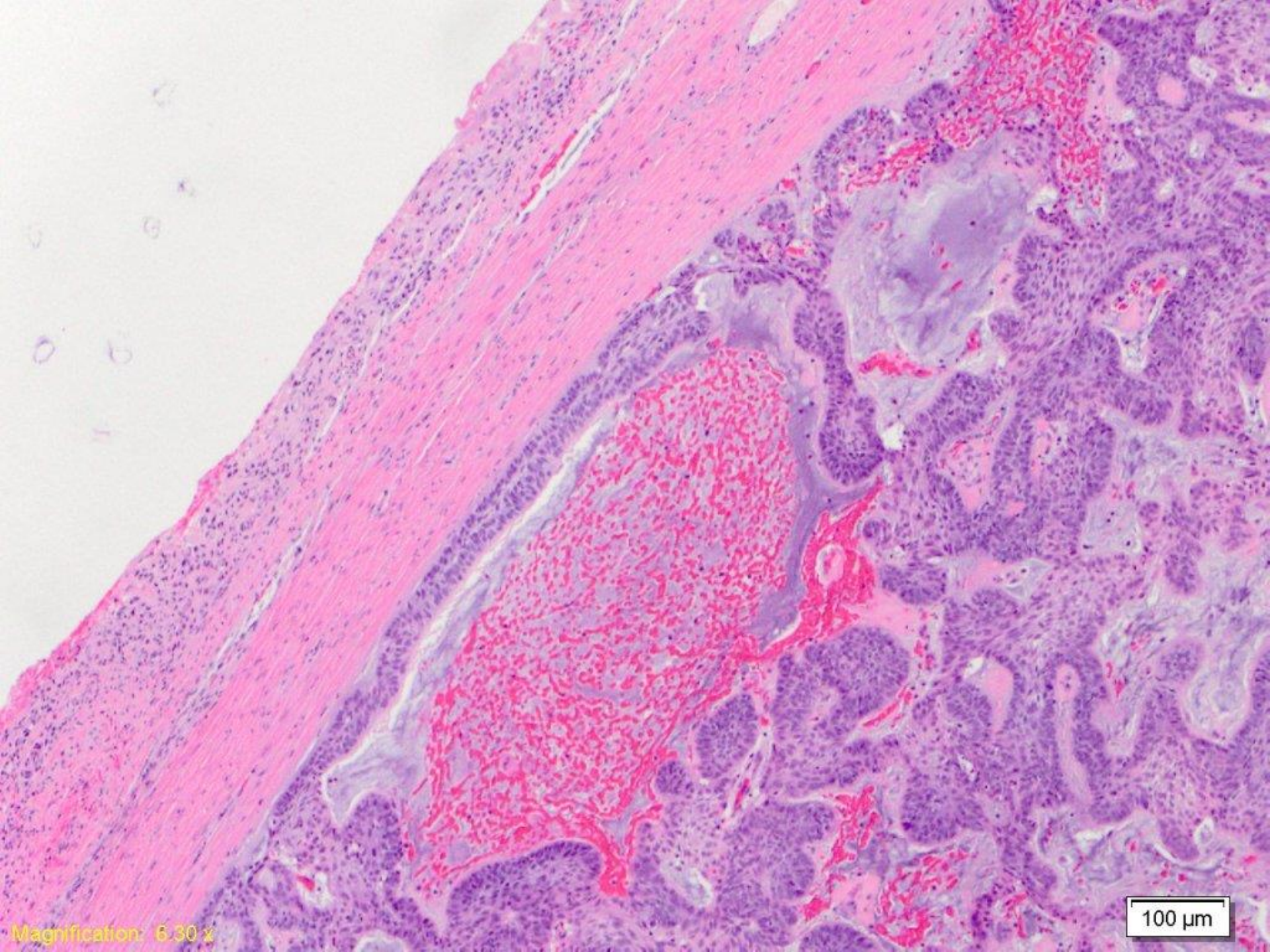
magnification: 3.52x

200 μ m



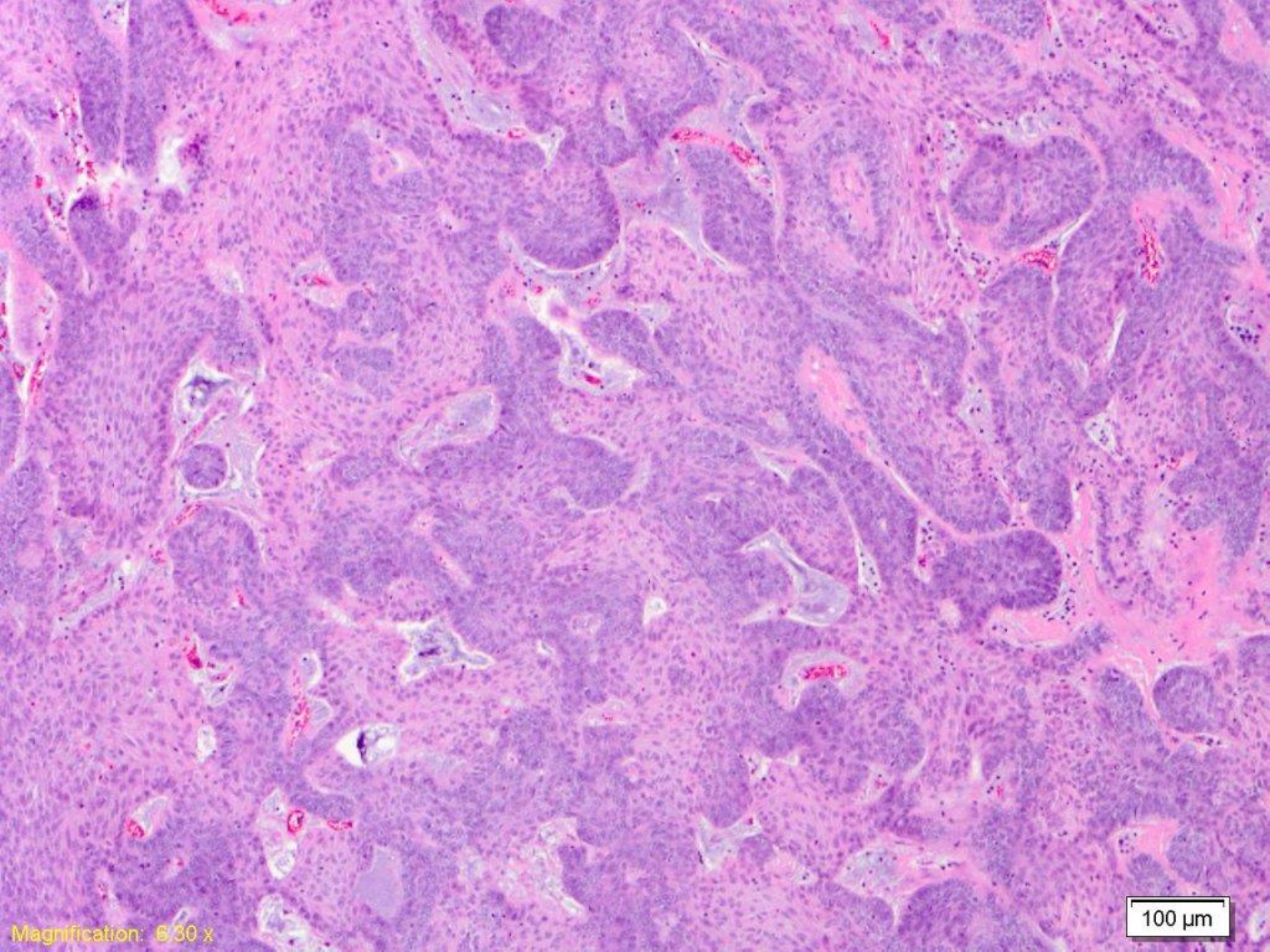
mucocele





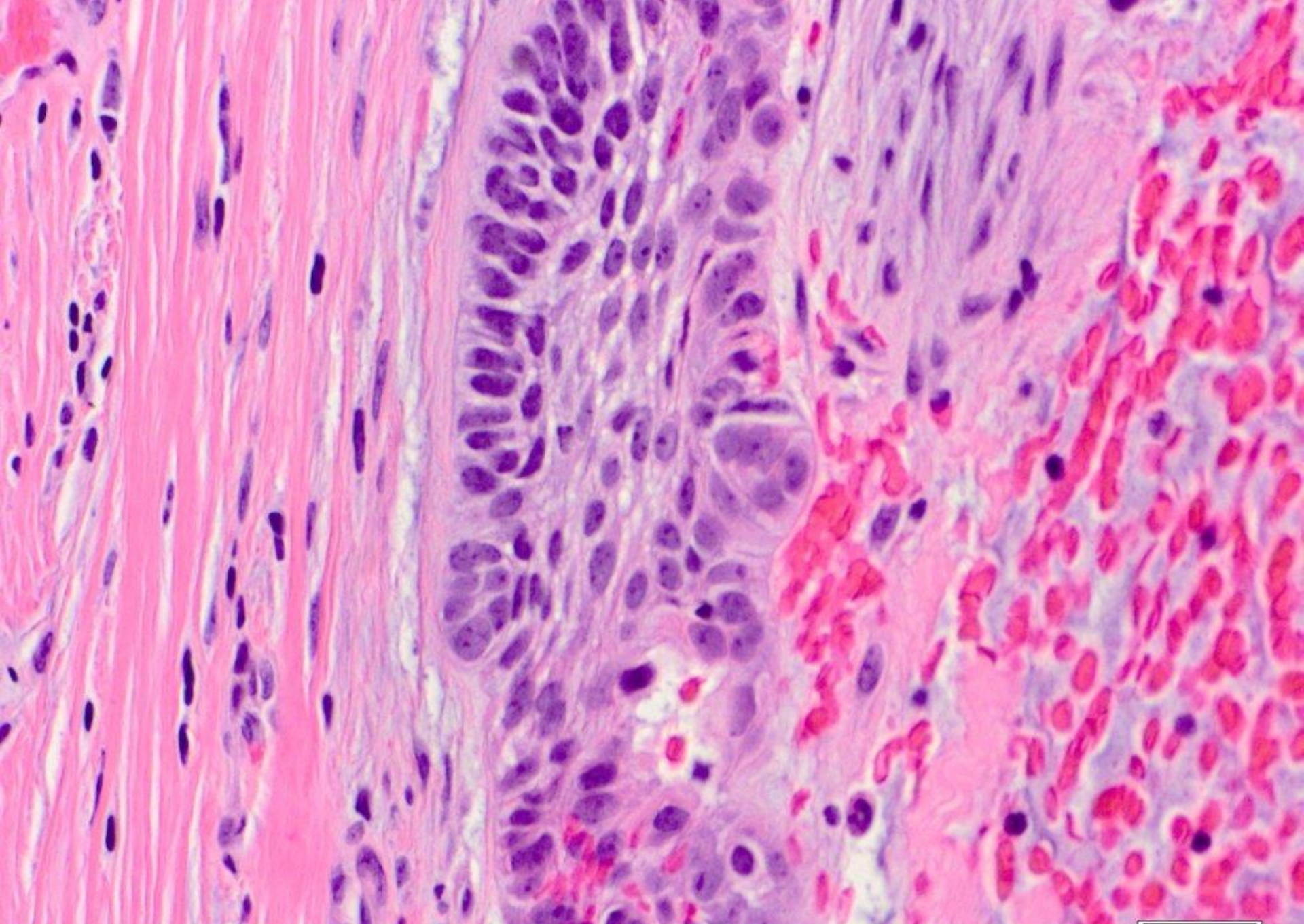
Magnification: 6.30 x

100 μ m

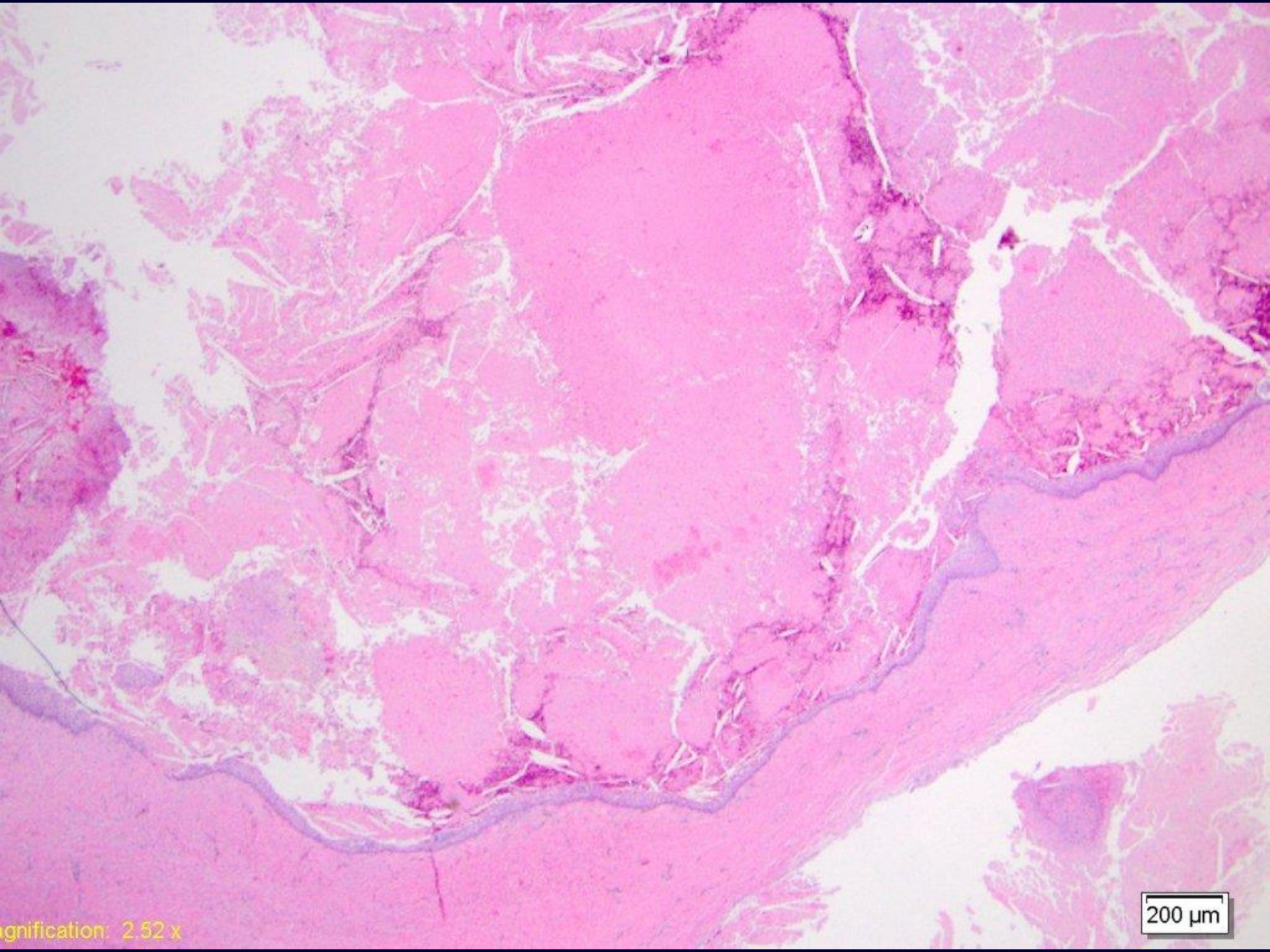


Magnification: 630 x

100 μ m

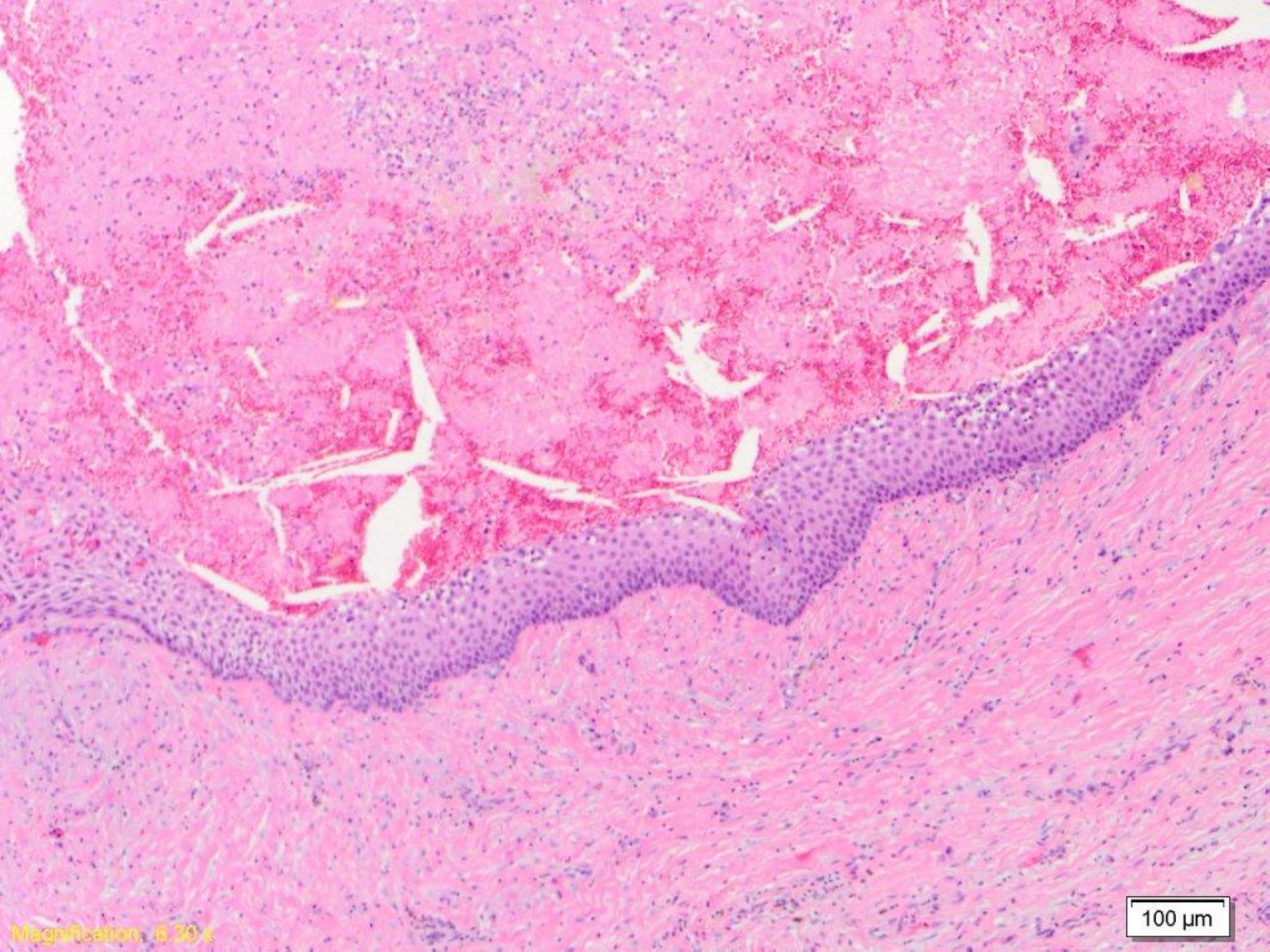


ameloblastoma



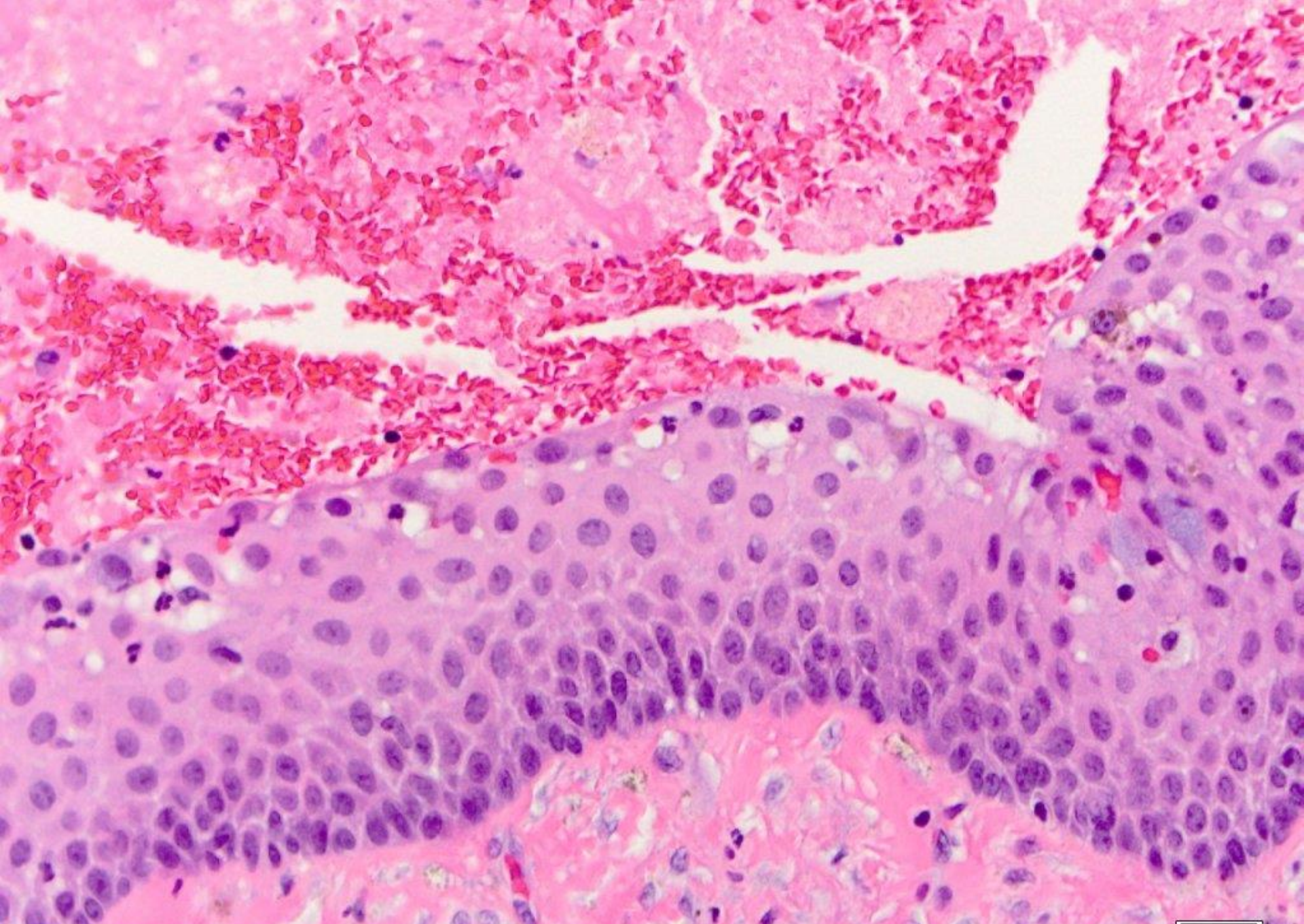
magnification: 2.52 x

200 μm

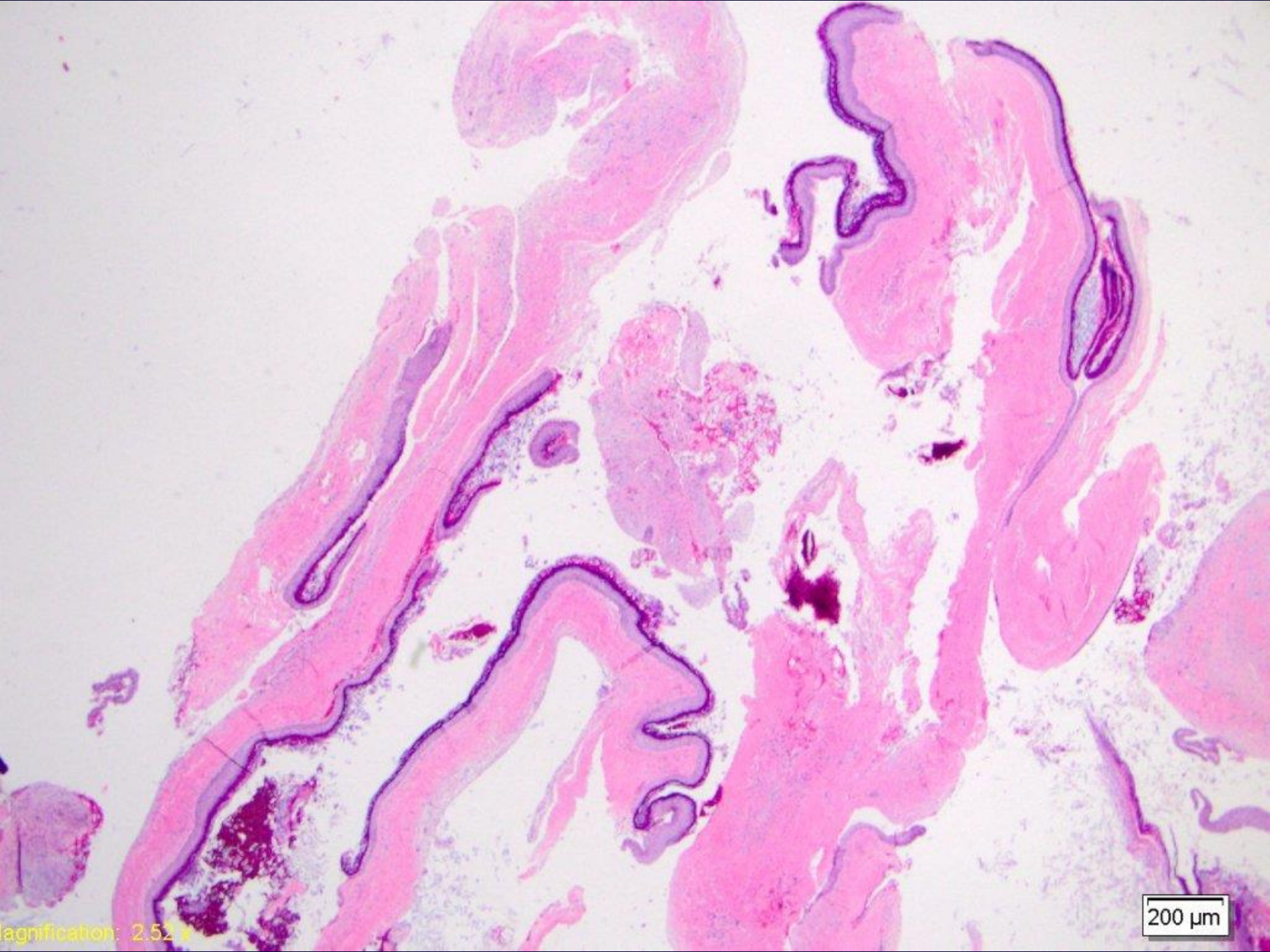


Magnification: 630 x

100 μ m

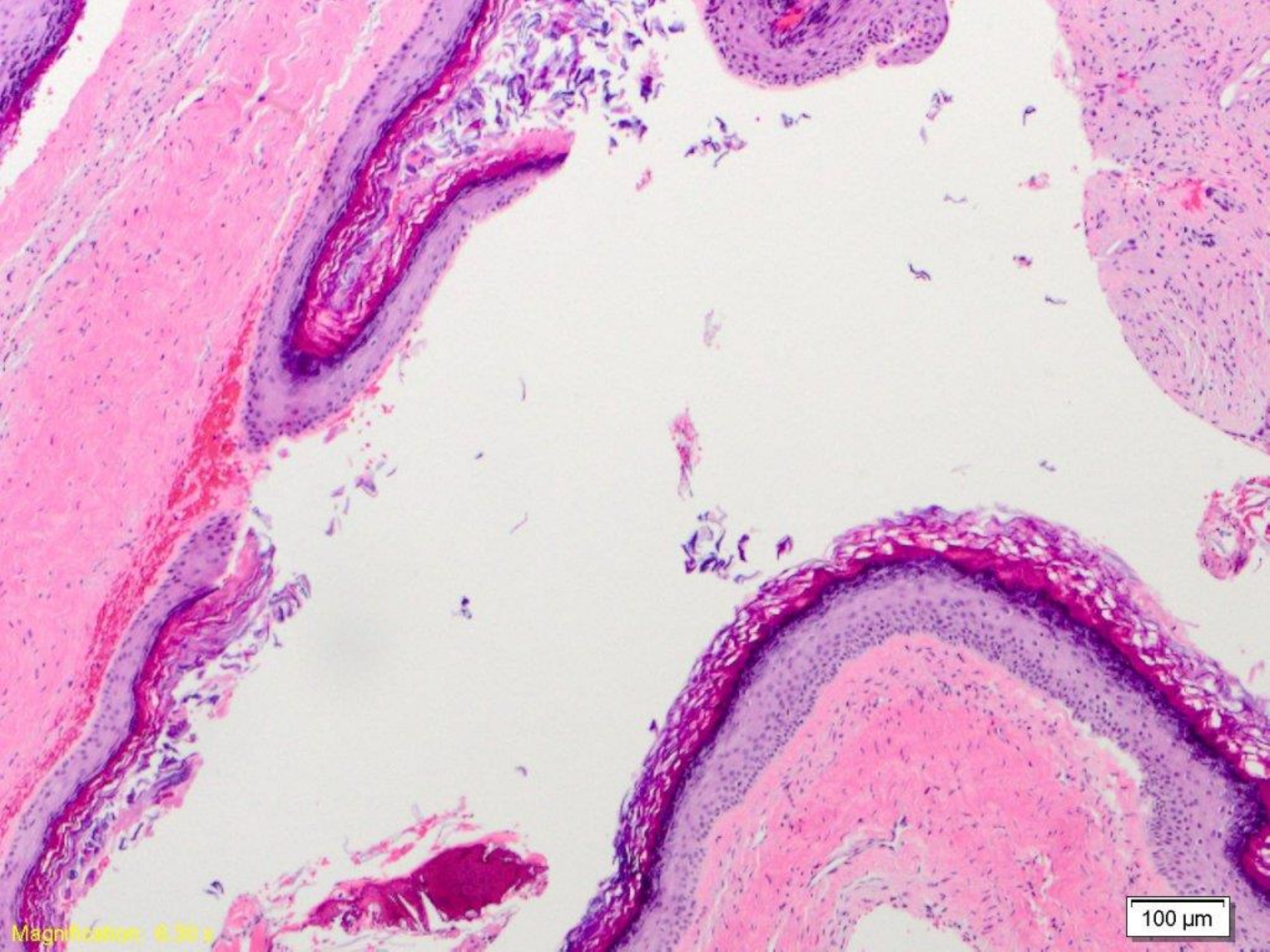


Glandular odontogenic cyst, with numerous cholesterol clefts



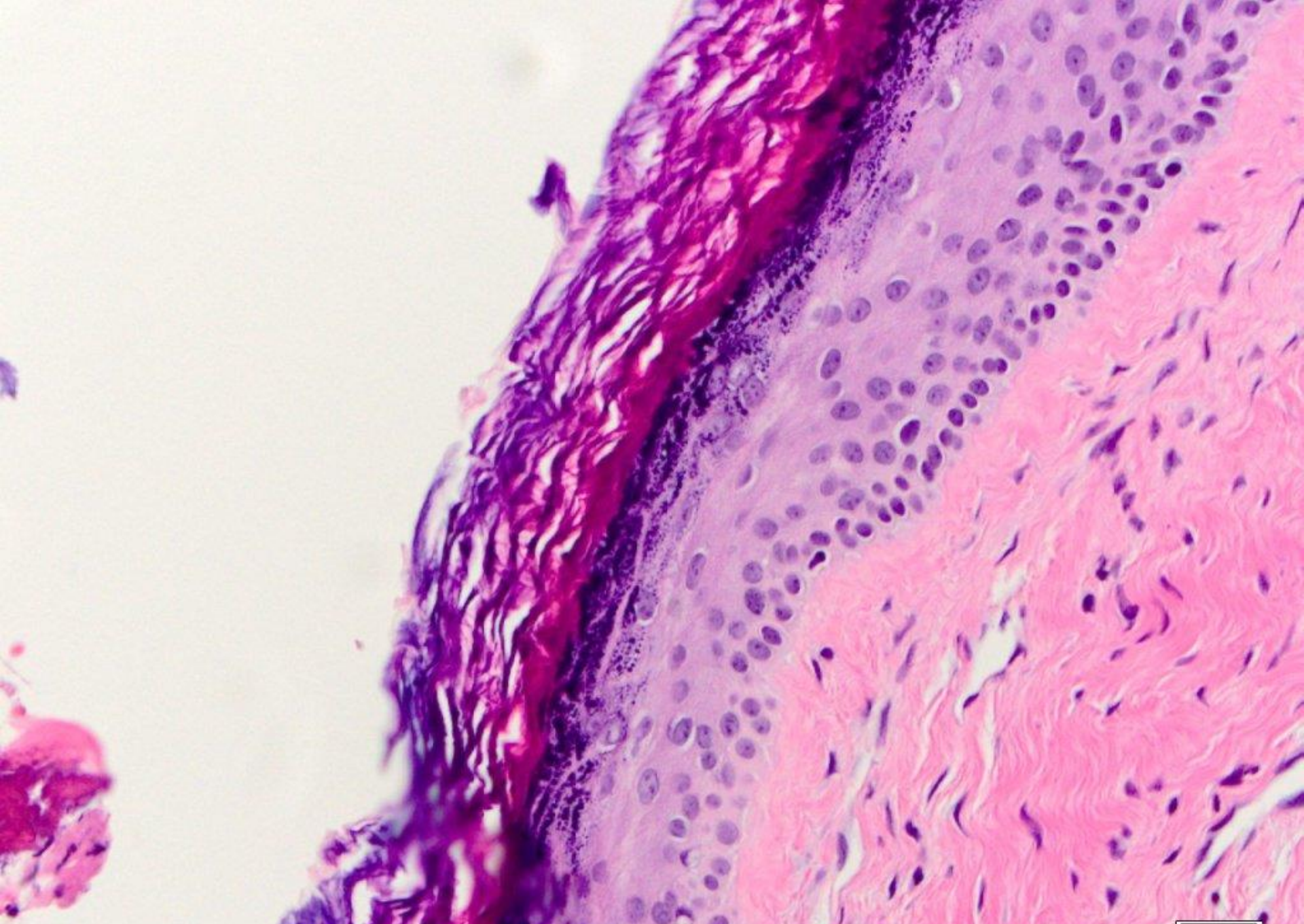
magnification: 2.52x

200 μ m

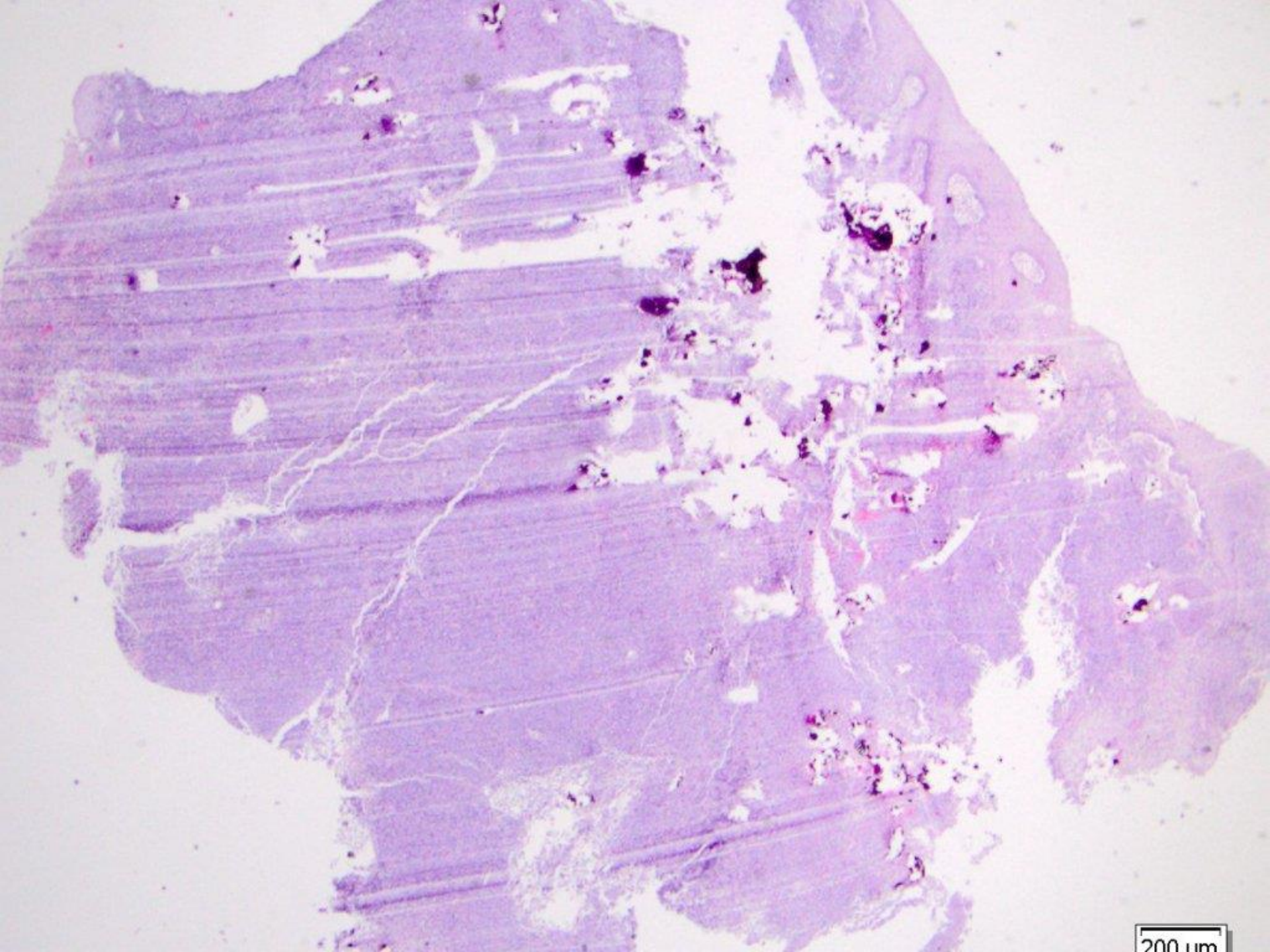


Magnification: 6.30x

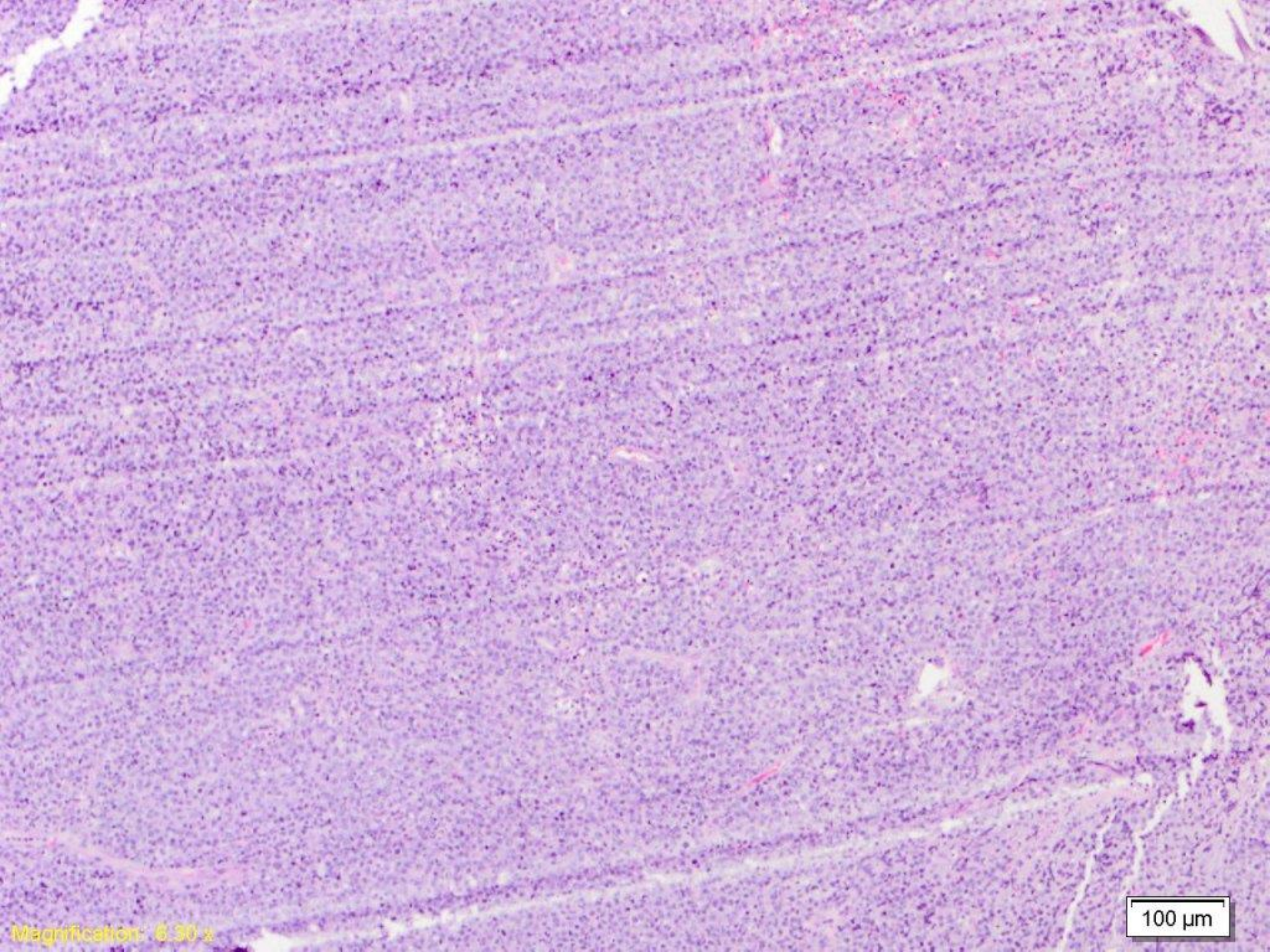
100 μ m



orthokeratinized odontogenic cyst

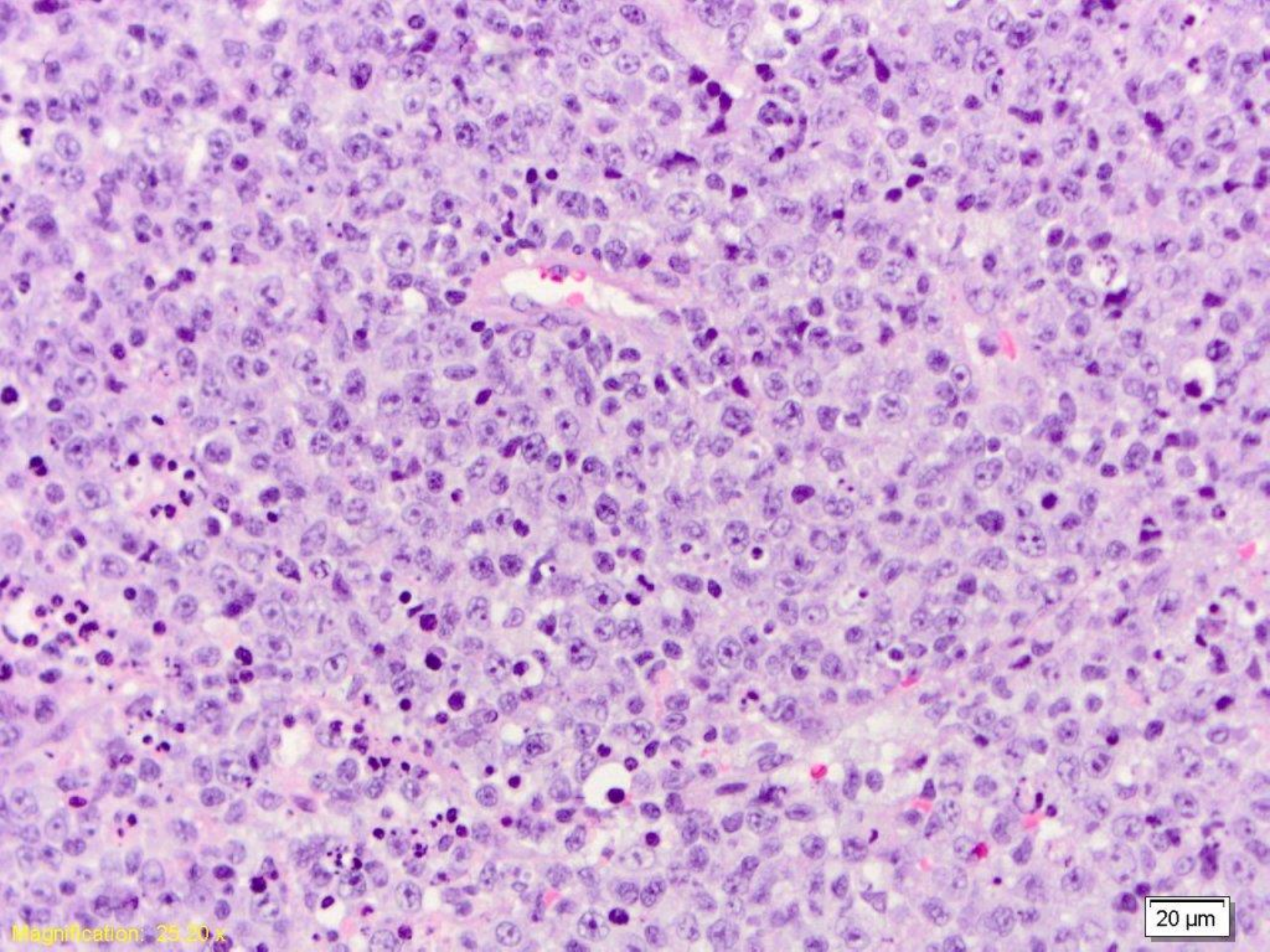


200 μ m



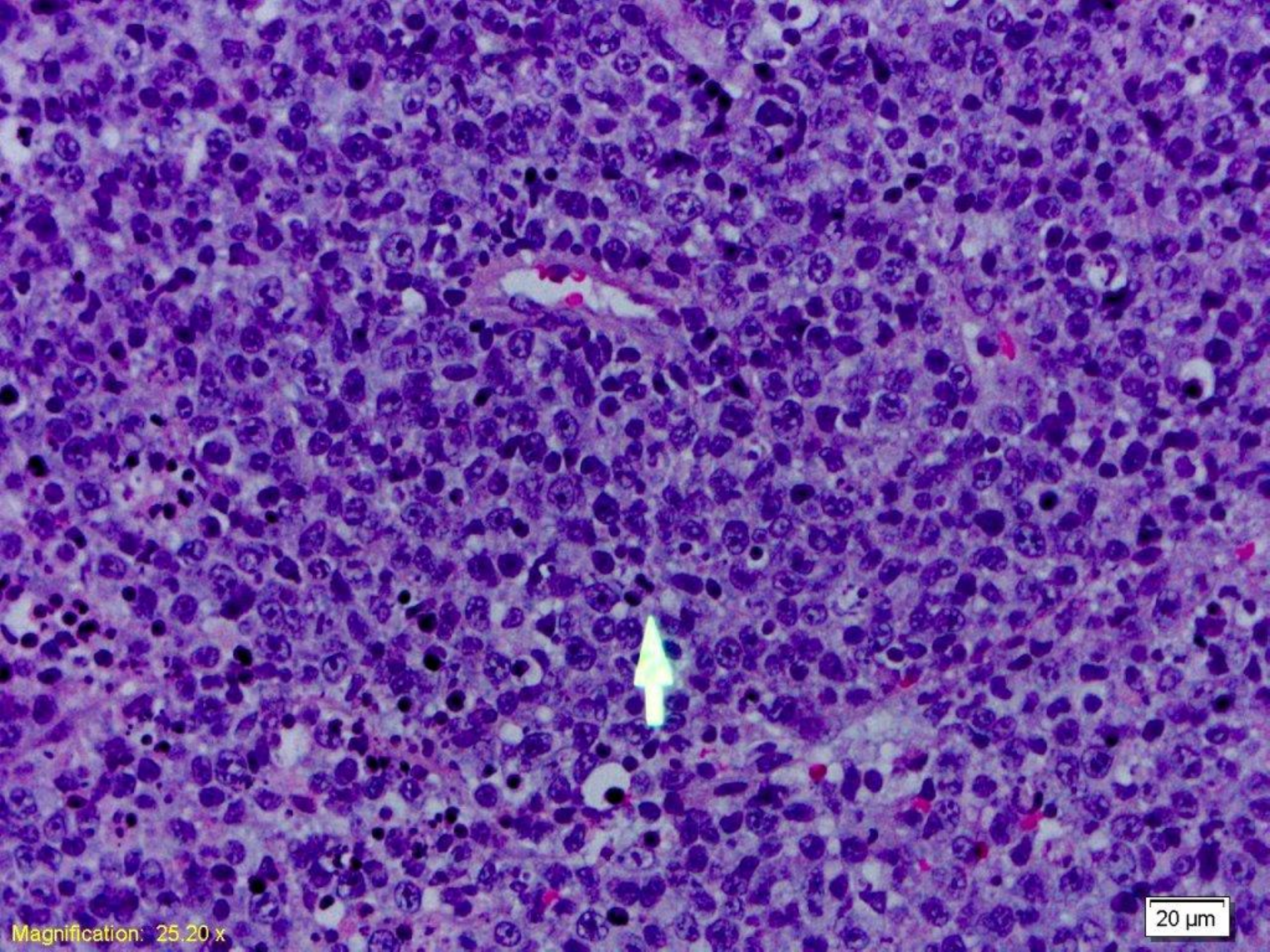
Magnification: 6.30 x

100 μm



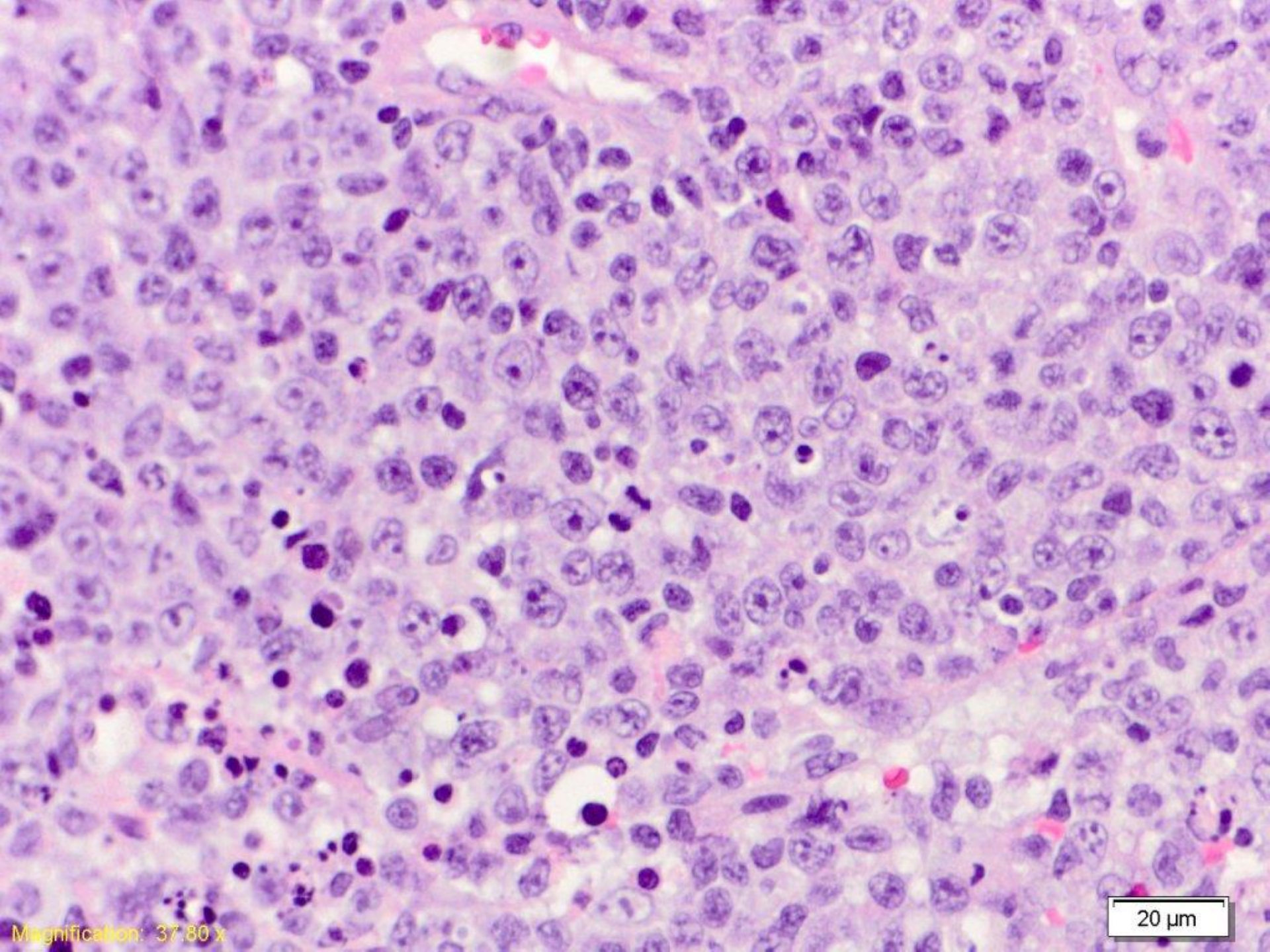
Magnification: 25.20 x

20 μ m



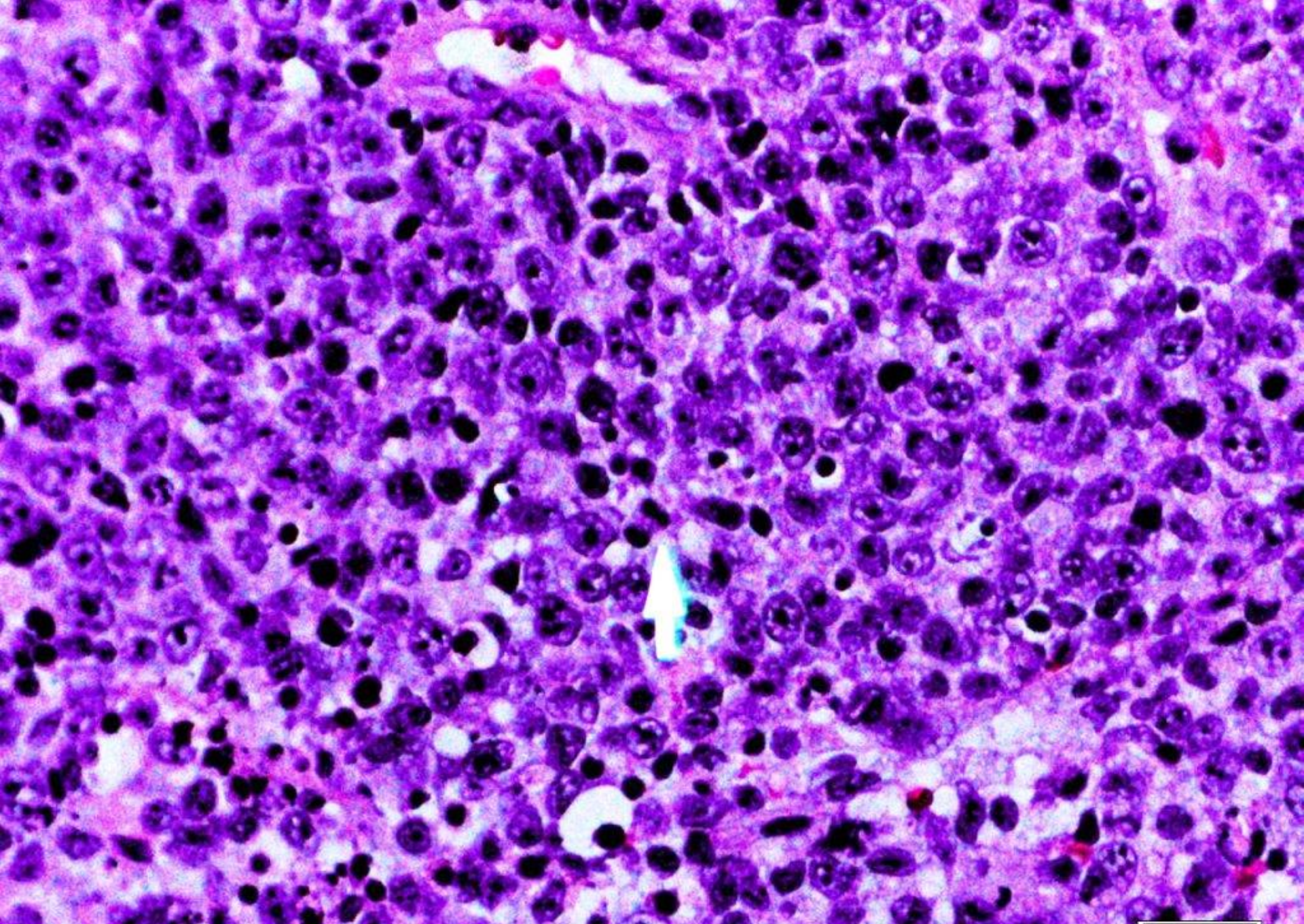
Magnification: 25.20 x

20 μm

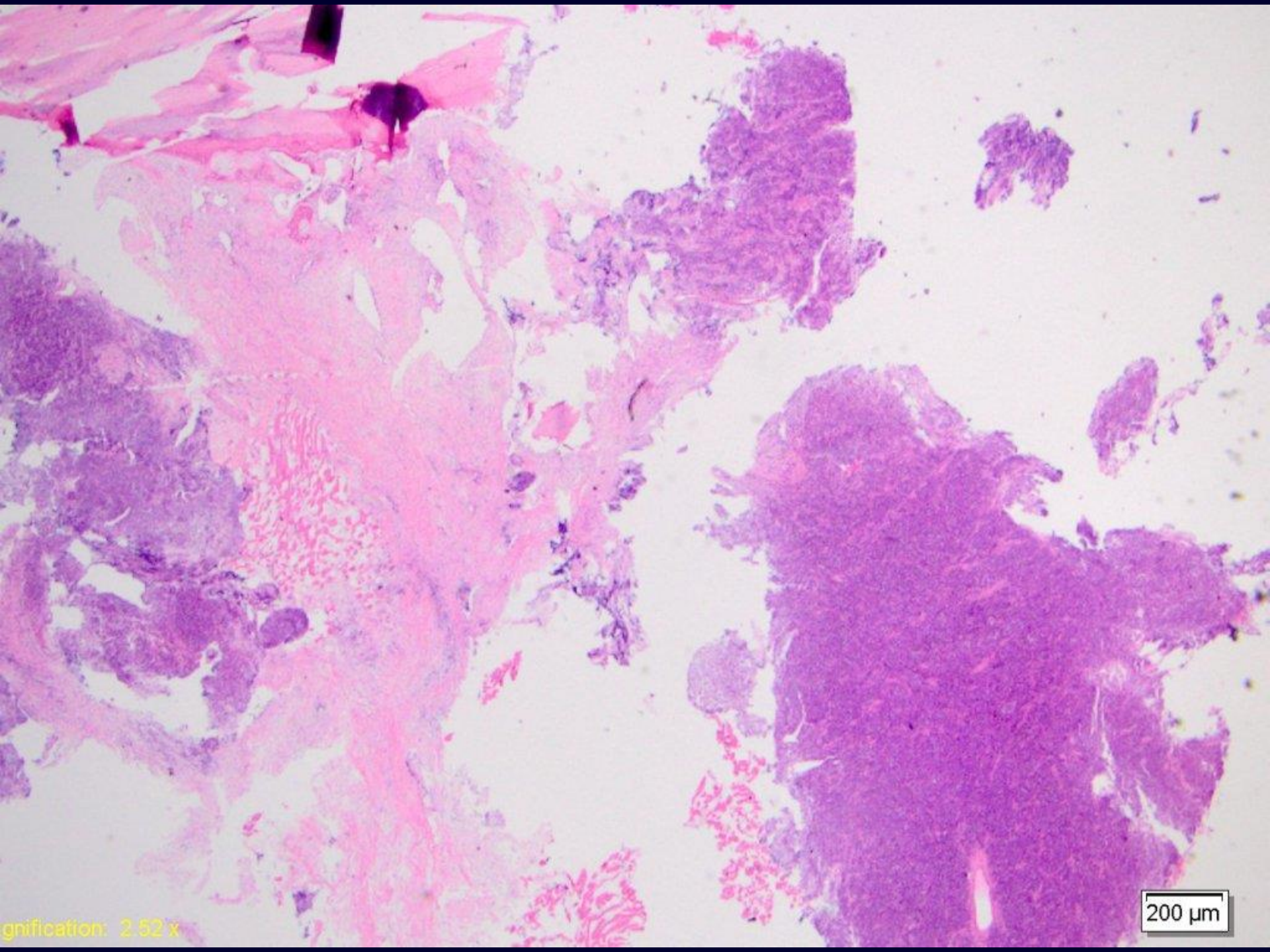


Magnification: 37.80 x

20 μ m

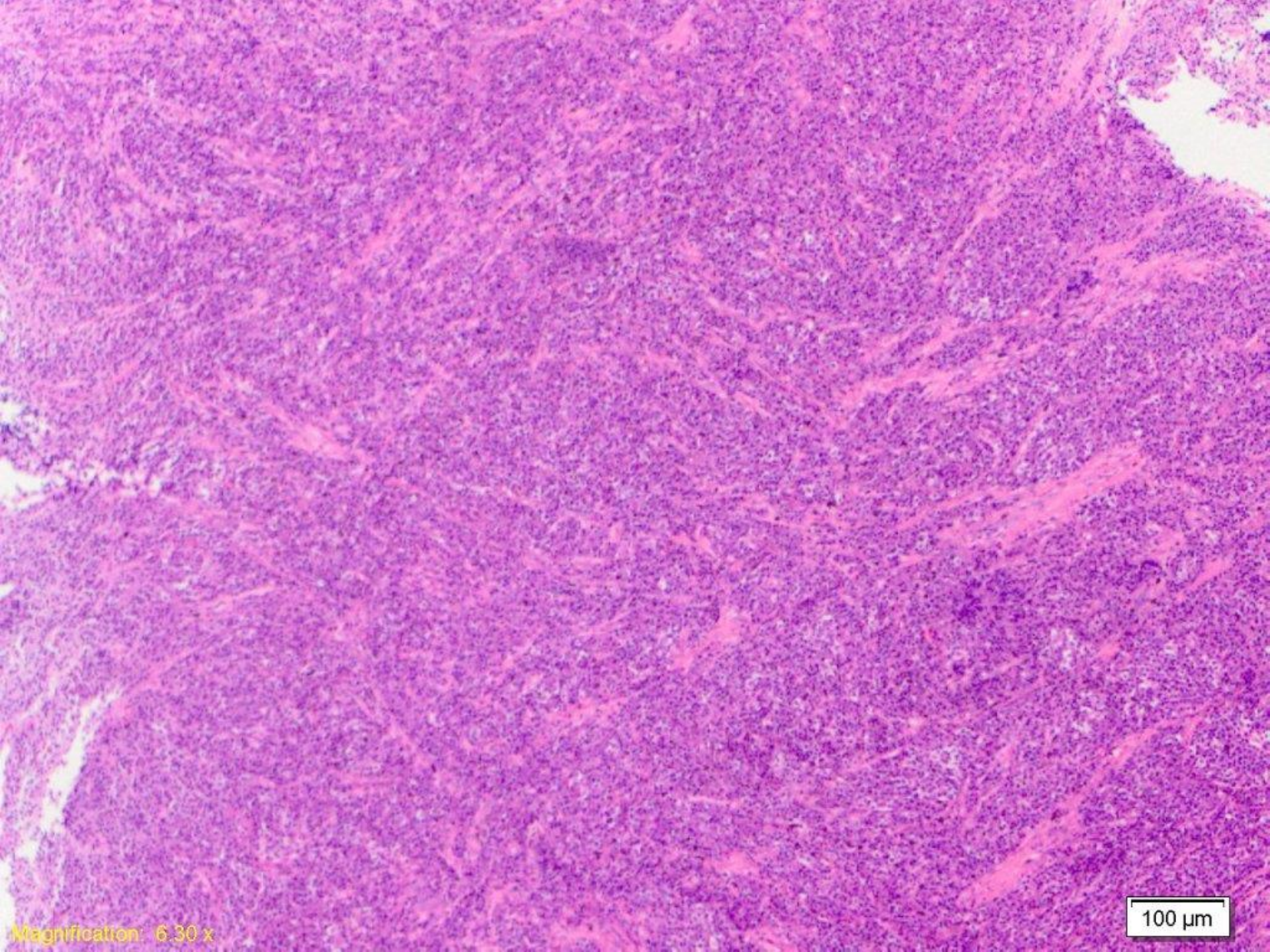


diffuse large B cell lymphoma



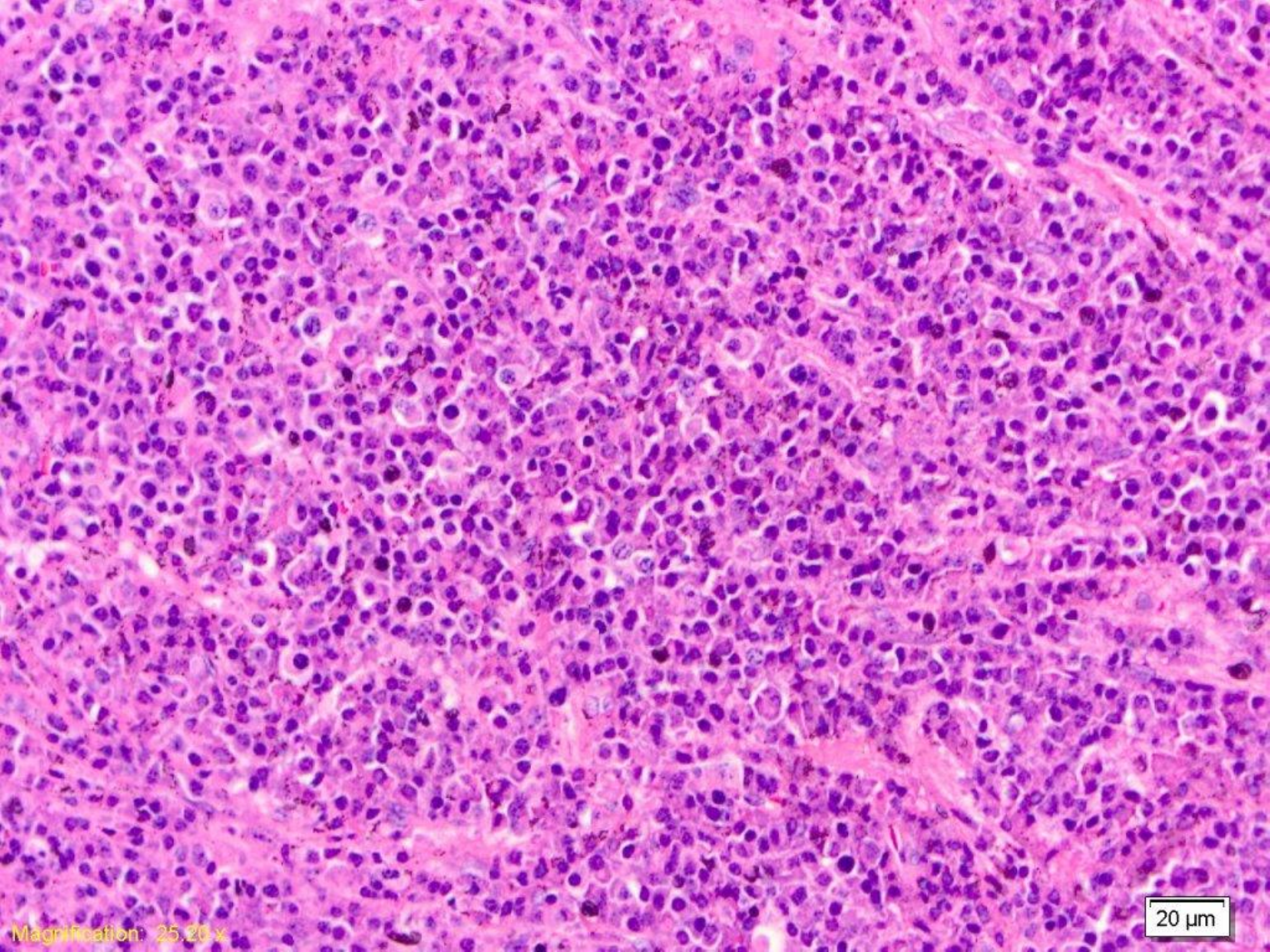
magnification: 2.52 x

200 μ m



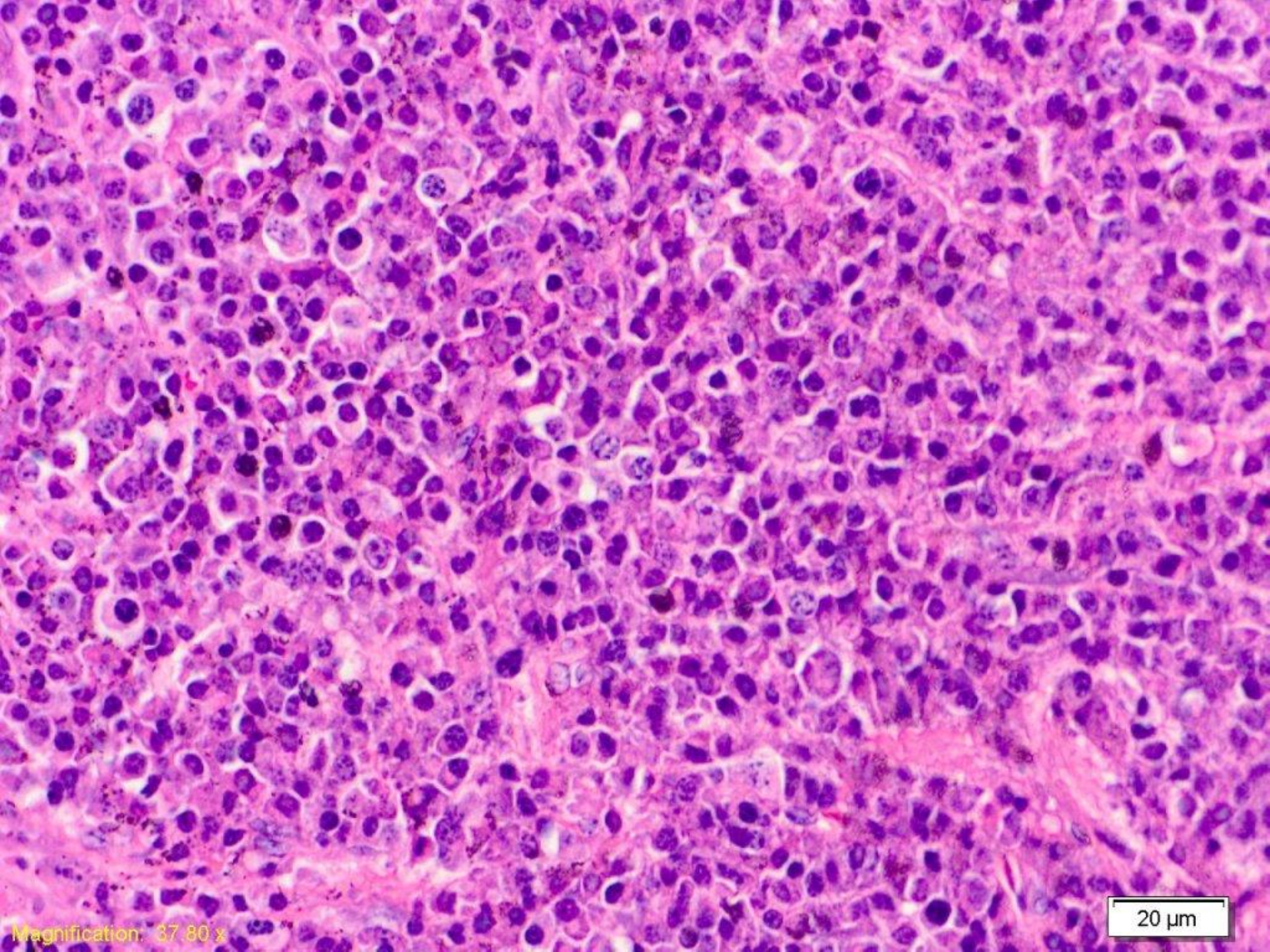
Magnification: 6.30 x

100 μ m



Magnification: 25.20 x

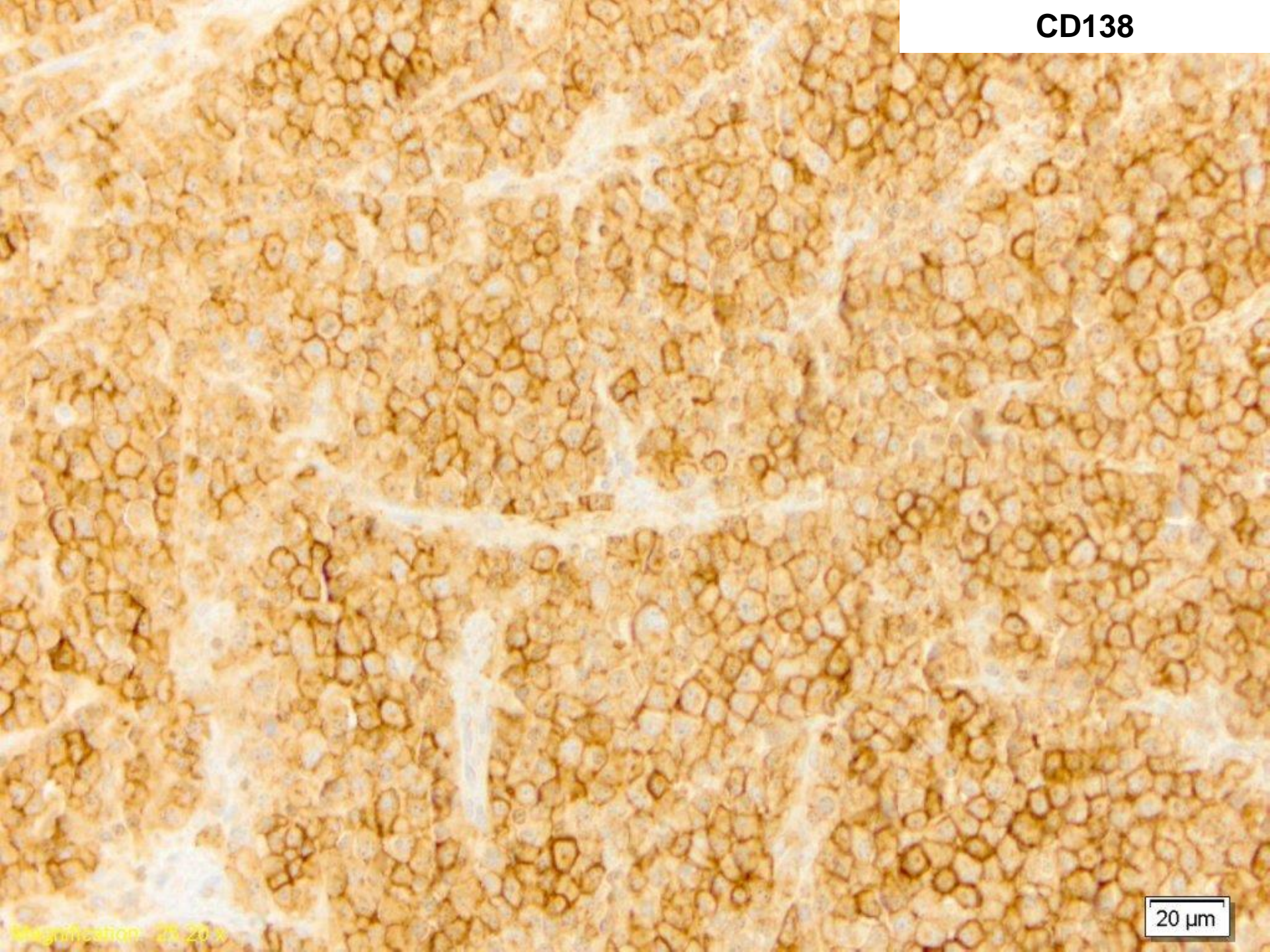
20 μ m



Magnification: 37.80 x

20 μ m

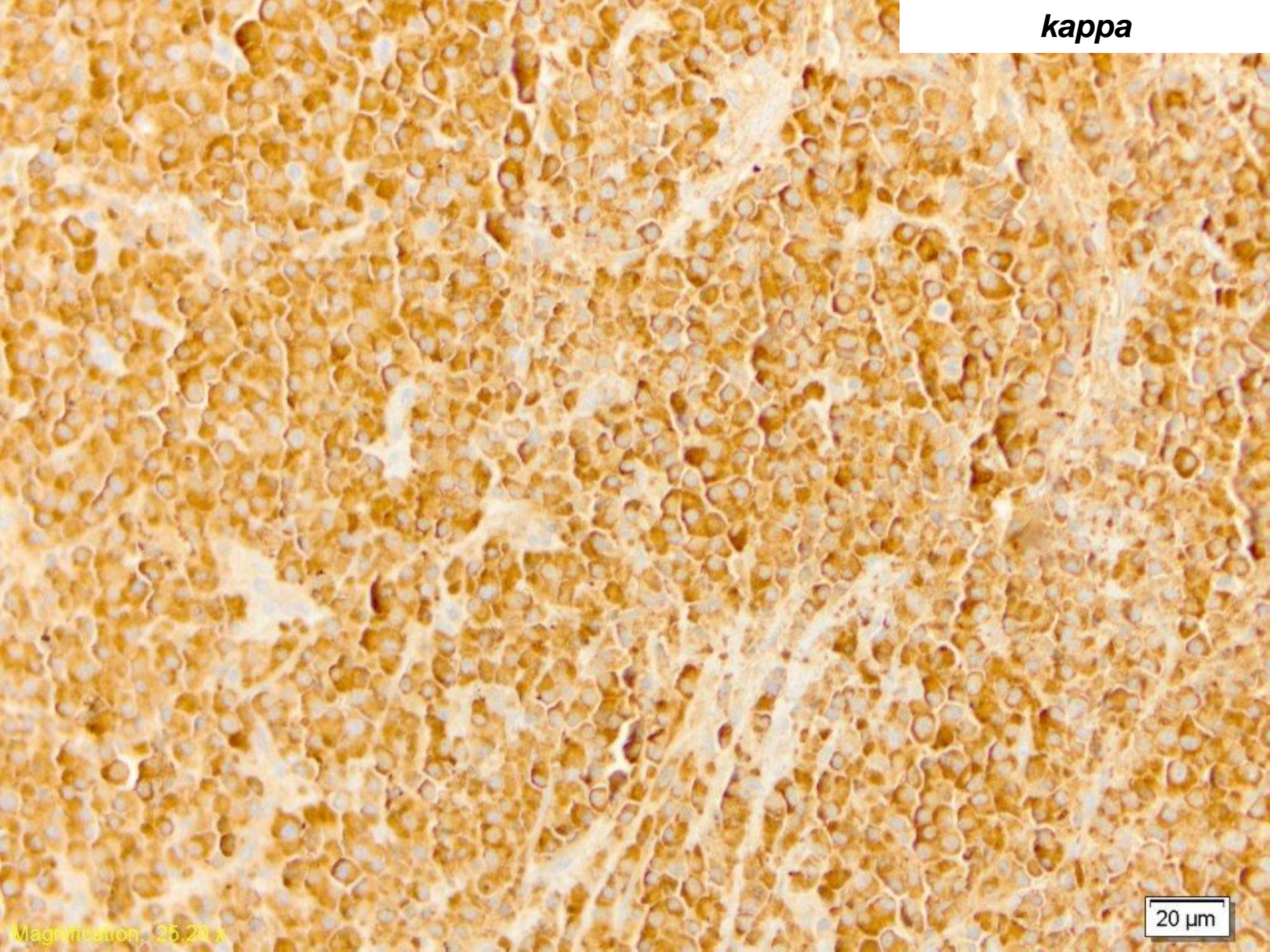
CD138



Magnification: 20x

20 μ m

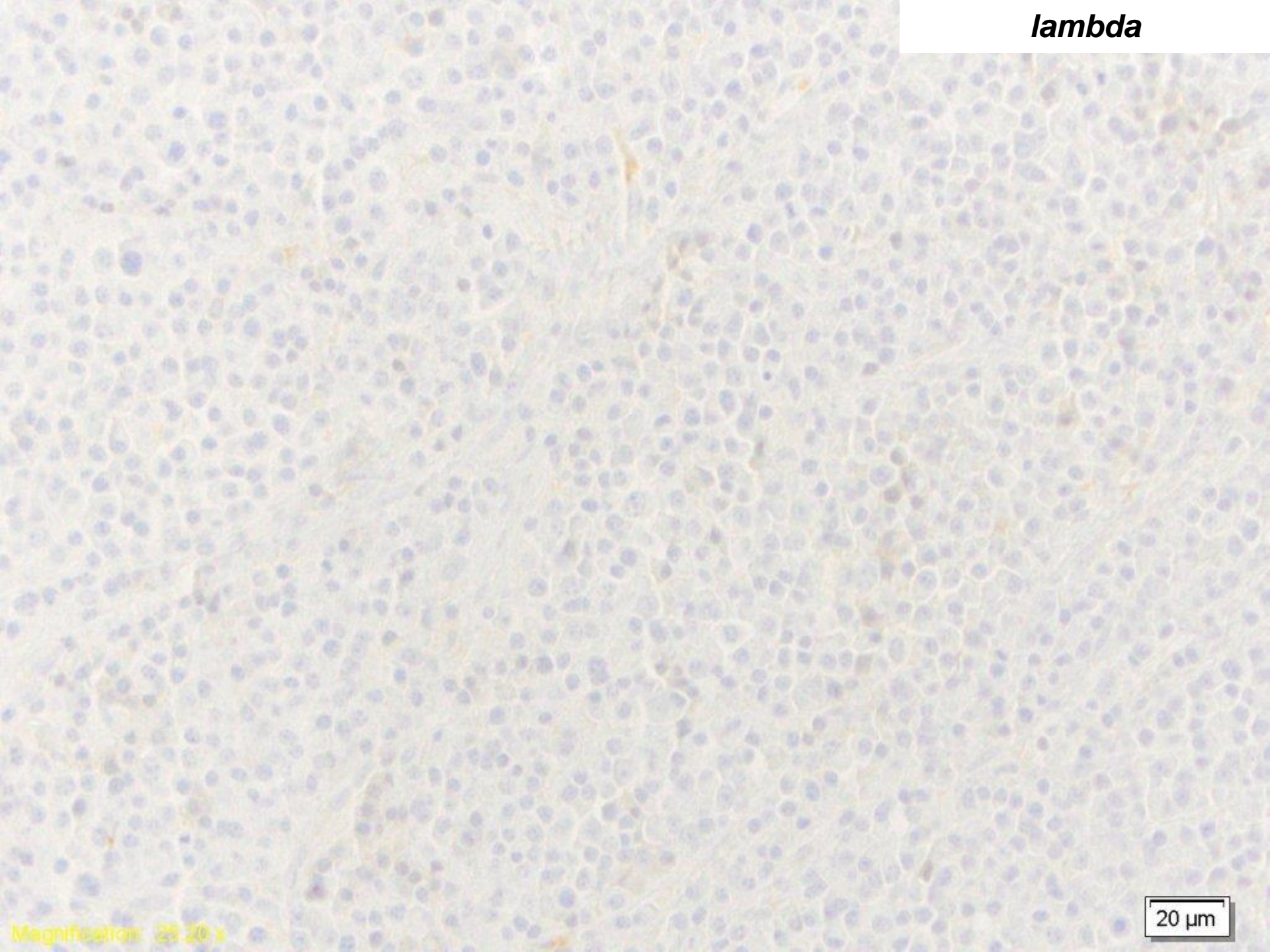
kappa



Magnification: 25,200 x

20 μ m

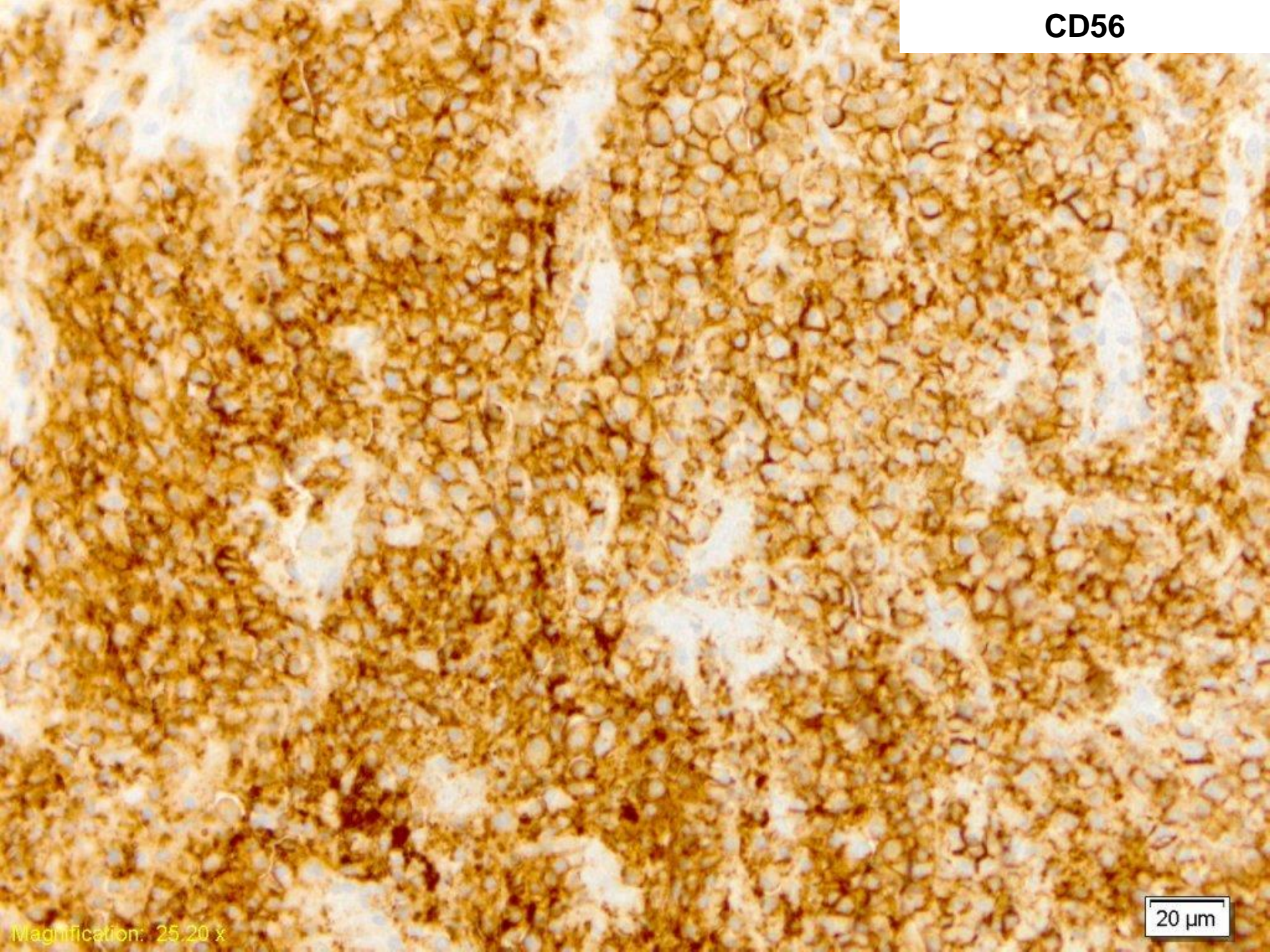
lambda



Magnification: 25.20

20 μ m

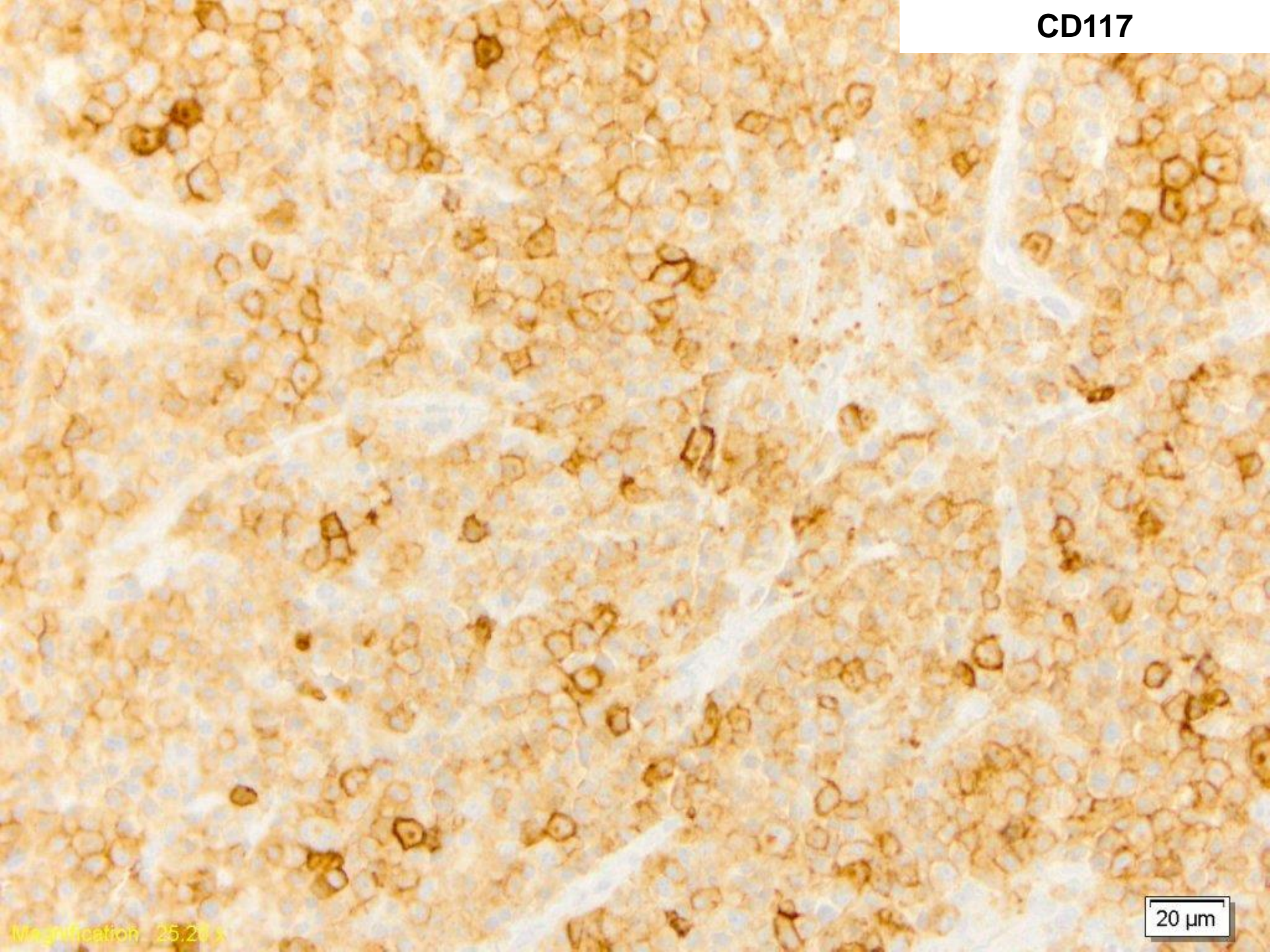
CD56



Magnification: 25.20 x

20 μ m

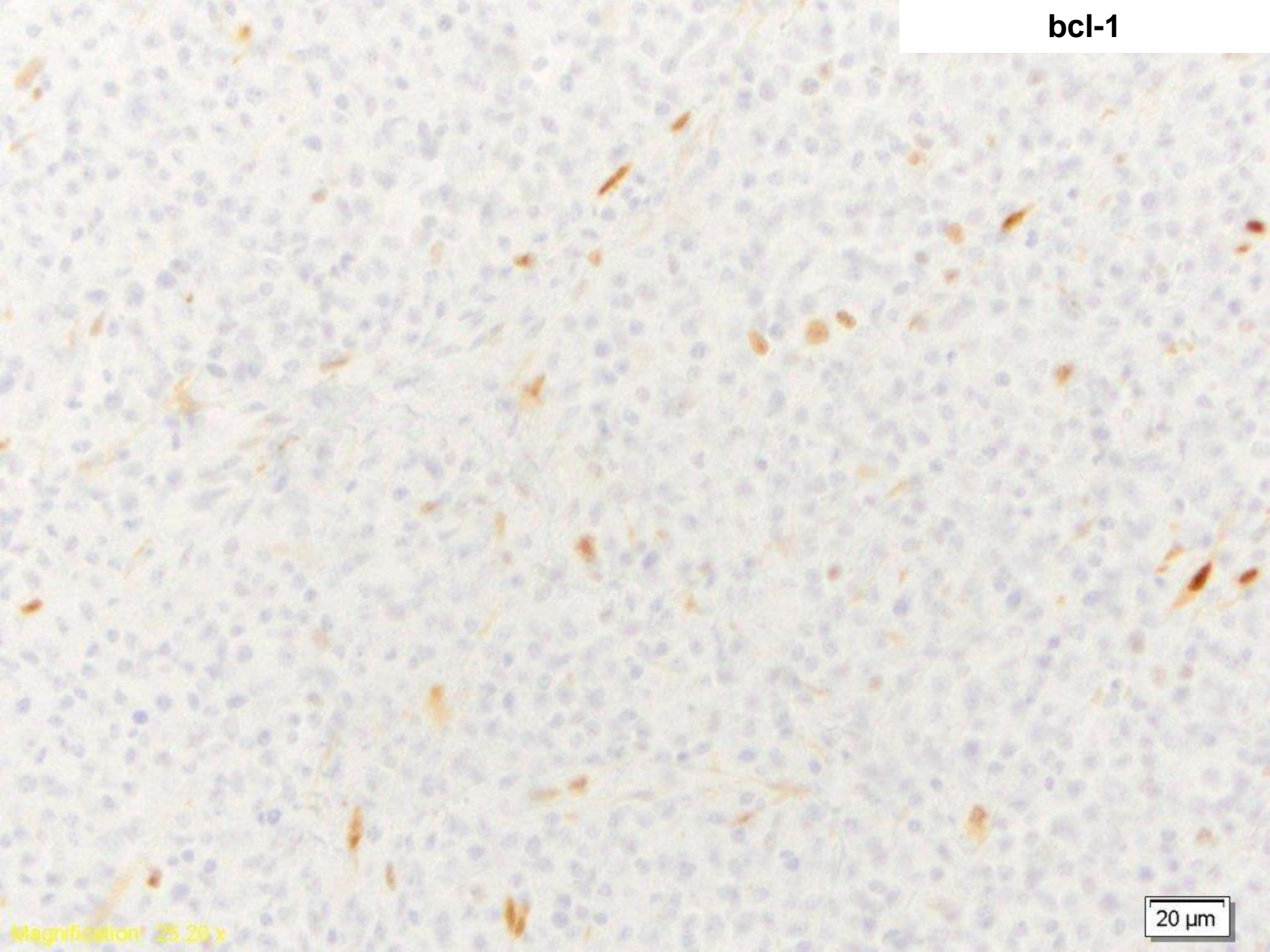
CD117



Magnification 25.2

20 μm

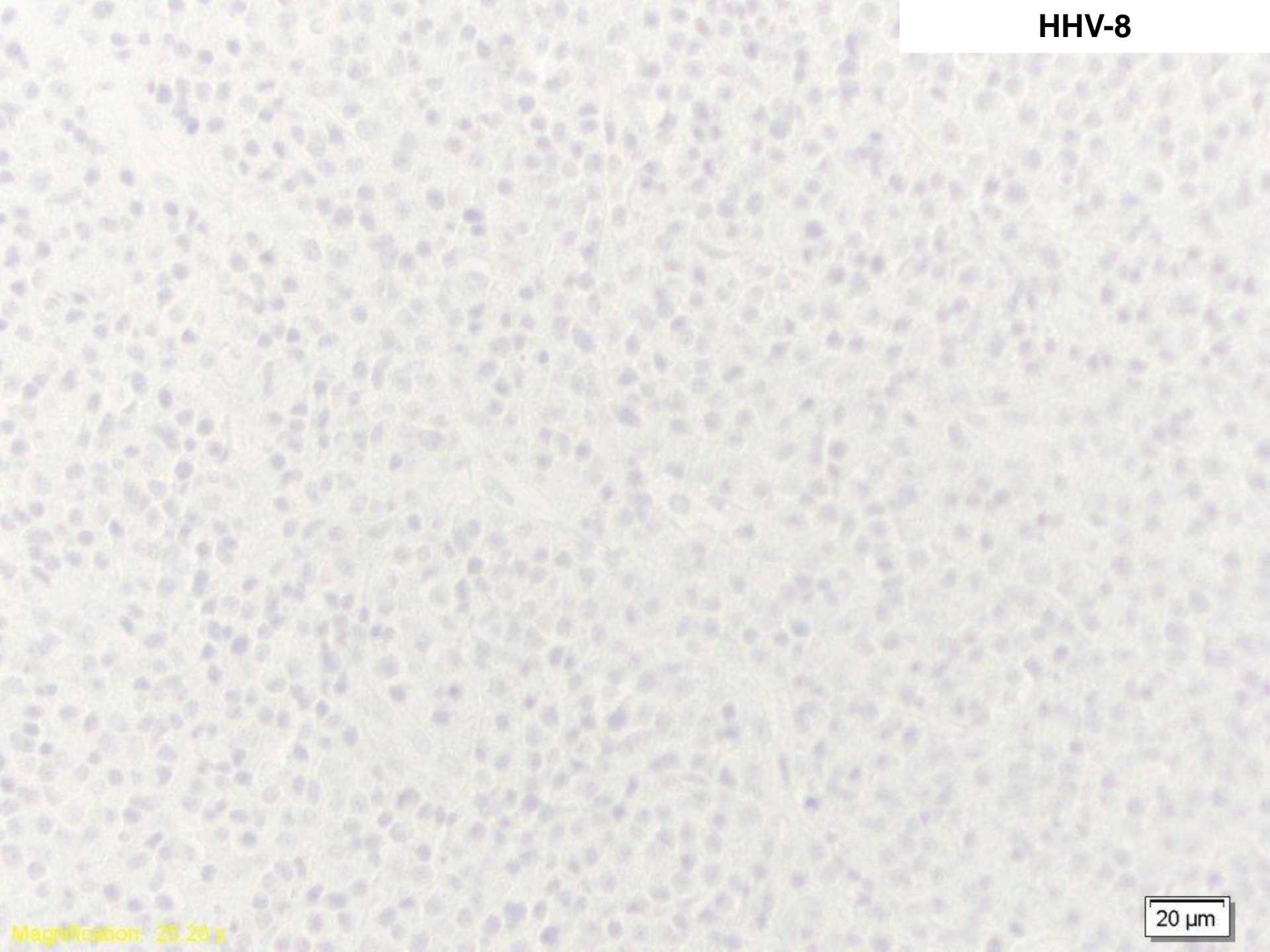
bcl-1



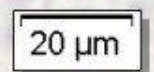
Magnification: 25.25 x

20 μm

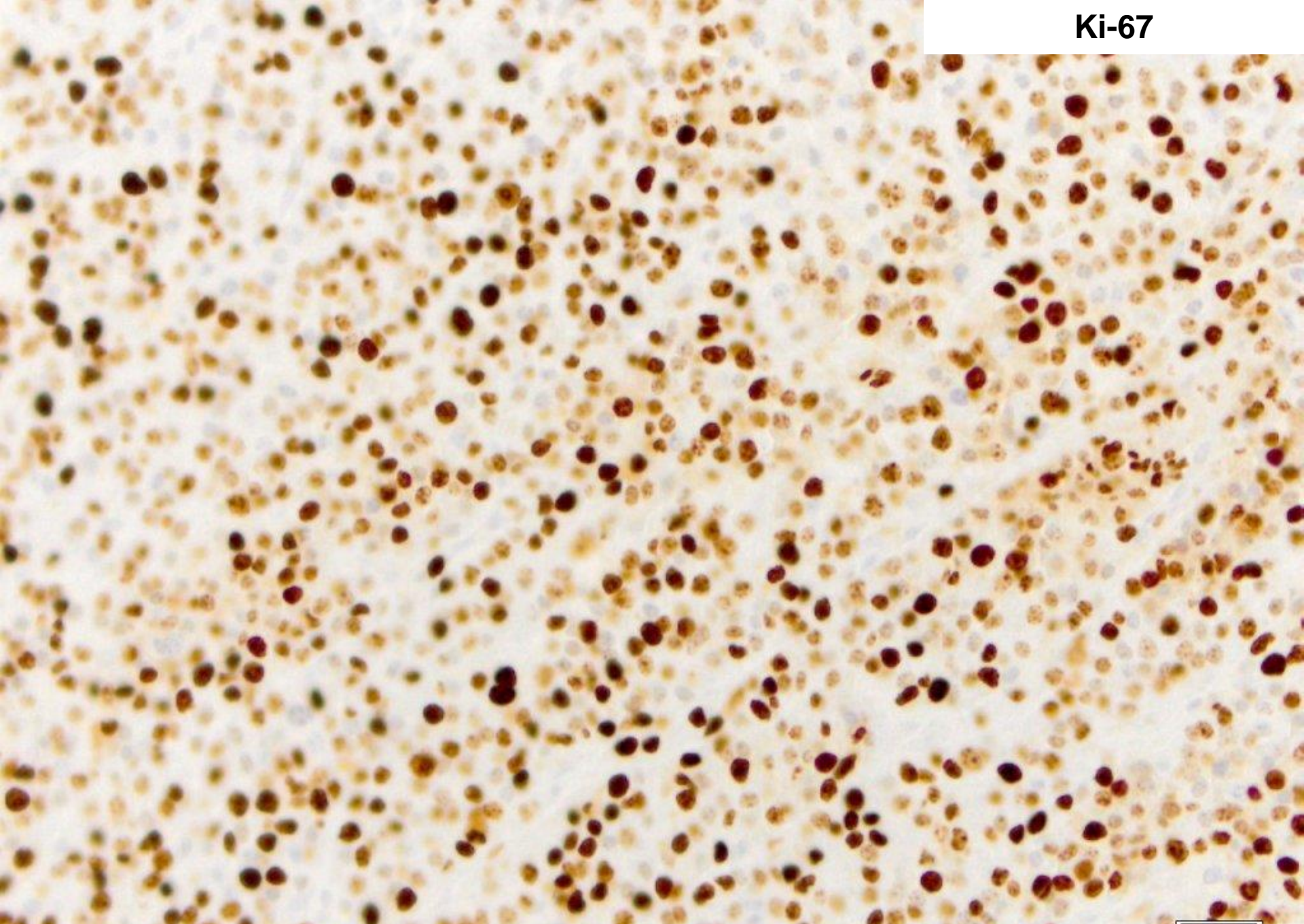
HHV-8



Magnification: 25.20x



Ki-67



myeloma